

DENTAL TECHNIQUE

A diagnostically and digitally driven tooth preparation protocol by using a patient monitoring tool with an intraoral scanner

Marco Valenti, DDS,^a Johannes H. Schmitz, DDS, PhD,^b Davide Cortellini, DDS, DMD,^c Alessandro Valenti, DDS,^d and Angelo Canale, CDT^e

Challenges during tooth preparation include the choice of finish line (margin geometry) and the thickness required for the restoration.¹ Excessive tooth preparation may lead to the need for endodontic treatment.² However, when additional space is provided, it will be easier to fabricate restorations with optimal contours and esthetics.^{3,4} New materials and techniques have enabled minimal tooth reduction,⁵⁻⁷ with minimum thickness restorations being placed with minimal or no tooth reduction.⁸⁻¹⁶ However, tooth preparations may be inadequate for the planned restoration.¹⁷

Different strategies have been developed to achieve a diagnostically driven conservative tooth preparation while providing adequate space for the restorative material. These strategies include the use of rotary instruments with a known cutting depth^{1,18} and the use of a silicone tooth preparation guide obtained from diagnostic waxing or from trial restorations.¹⁹⁻²¹ More recently, 3-dimensionally printed tooth preparation guides from a virtual waxing²²⁻²⁴ or completely digital preparation guides have been developed.²⁵⁻²⁷

Digital technology can allow precise control over the thickness obtained during the preparation procedures. Digital feedback has been shown to be helpful by displaying how much tooth structure has been removed, in improving preparation skills,¹⁶ and in giving indications regarding the appropriateness of the preparation

ABSTRACT

Finding the right balance between the preservation of tooth structure and providing adequate space for the restorative material is a major challenge in prosthetic dentistry. A technique is presented using the patient monitoring tool available in standard software programs of an intraoral scanner to constantly monitor preparation dimensions in relation to the optimal definitive restoration. (J Prosthet Dent 2021;■:■-■)

reduction for the specific restoration planned by the clinician.^{17,25,27}

TECHNIQUE

This technique can be used during the preparation procedure of natural teeth for ceramic veneers, crowns, or fixed partial dentures. To control the preparation both in terms of space and shape, it is necessary to scan the ideal initial situation or initial ideal scan (IIS) of the tooth to be restored. If a tooth needs a restoration because of abrasion or erosion, a dental laboratory technician can produce a digital waxing that will be used to create a trial restoration. This will serve as the initial ideal situation than can then be scanned as the IIS. When a tooth needs an extensive restoration or when it is malpositioned, the initial scan can be substituted by a digital waxing that can be imported into the intraoral scanner software program (TRIOS; 3Shape A/S) and is referred to as the initial reference scan.

1. Start producing the IIS, which will act as the reference scan for the next steps (Table 1).

^aPrivate practice, Pordenone, Italy.

^bPrivate practice, Milan, Italy.

^cPrivate practice, Riccione, Italy.

^dPrivate practice, Pordenone, Italy.

^eDental Lab owner, Rimini, Italy.

Table 1. Types of initial ideal scan which will act as reference scan for subsequent steps

Tooth Type	Initial Scan	Initial Scan Used as Reference Scan for Analysis	Digital Waxing Used as Reference Scan for Analysis	Trial Restoration Used as Reference Scan for Analysis
Ideal tooth	Yes	Yes	No	No
Additive approach	Yes	No	No	Yes
Subtractive approach Inadequate tooth form	Yes	No	Yes	No

- a. If there is already an ideal situation, choose the “scan only” option in the left menu and scan the initial situation before starting the tooth preparation (Fig. 1).
 - b. If the planned restorations are additive, the dental laboratory technician will create a digital waxing from an initial scan and then print it to create a silicone tooth preparation guide (Fig. 2). After trial restoration placement, it will be scanned as the IIS.
 - c. If it is necessary to subtract a portion of the tooth to be restored, the dental laboratory technician will create a purely digital waxing. This file can then be imported into the software program (TRIOS; 3Shape A/S) as a “scan only” (Fig. 3).
2. In a scenario similar to step 1a or 1b, start tooth preparation using calibrated rotary instruments (Fig. 4A). Maintain a conservative approach to gradually proceed with further corrections after evaluation through the Patient Monitoring function (TRIOS; 3Shape A/S) (Fig. 4B).
 3. Create a new case copying the IIS with the intact teeth. Trim the prepared teeth and scan the same teeth that have now been prepared (Fig. 5).
 4. Open the IIS case (natural 1A, trial restorations 1B, or digital waxing 1C). Choose the Patient Monitoring button in the upper menu. Choose the ones to be compared with the IIS (ideally the one with the prepared abutments) (Fig. 6).
 5. The software program will automatically recognize the scans and the teeth. The “scan comparison” and the “sectioning tool” (left menu) are now available to evaluate the preparations against the IIS (Fig. 7). On the 3-dimensional image, a sectioning reference can be added in any plane in the 3-dimensional space. By moving the section tool, it is possible to evaluate the distance between the prepared surface and the trial restoration or the initial situation, the interocclusal space, and a 360-degree evaluation of the preparation (Fig. 8). For every tooth to be analyzed, the process must be repeated to erase the section previously used to avoid incorrect

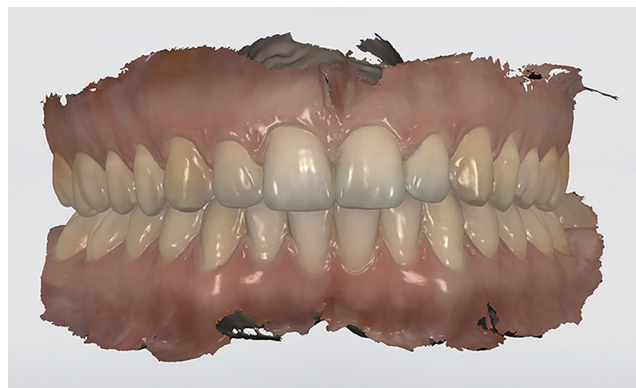

Figure 1. Scan of initial situation with intact teeth and correct shape.

angulations relative to the tooth axis. The scan comparison tool has a color scale that allows the clinician to determine the 2 thresholds (too thick or too thin) of the preparation and identify areas that need further preparation (Fig. 9).

6. Adjust the preparation accordingly and go back to step 3 (copy the IIS, trim the tooth prepared, scan it, and start a new comparison with the patient monitoring tool) until the tooth preparation is satisfactory.
7. When the tooth preparation is satisfactory, prepare a new case as a prosthetic case and send it to the dental laboratory technician.

DISCUSSION

The process should always start with a scan or digital waxing representing the ideal shape and size of the tooth to be restored to make an ideal tooth preparation to fabricate the restoration. If an interim restoration is used as the reference in the procedure described, it must be as close as possible to the definitive restoration. An ideal digital waxing is preferred as a reference rather than an interim restoration.

The use of a physical index or tooth preparation guide can be cumbersome and empirical.²⁸ Furthermore, each plane in space must be analyzed separately. It is therefore impractical to receive visual feedback as the preparation progresses. Being able to evaluate the adequateness of the preparations before sending impressions or scans to the dental laboratory technician is important to improve the efficiency of the workflow.²²⁻²⁵ The patient monitoring tool is available for all TRIOS 3Shape users and was initially developed to evaluate orthodontic movement and patients with tooth abrasion. When using a different intraoral scanner without a patient monitoring function, the prepared tooth can be compared with an ideal reference scan by sending the standard tessellation language (STL) files generated by using a scanner to a

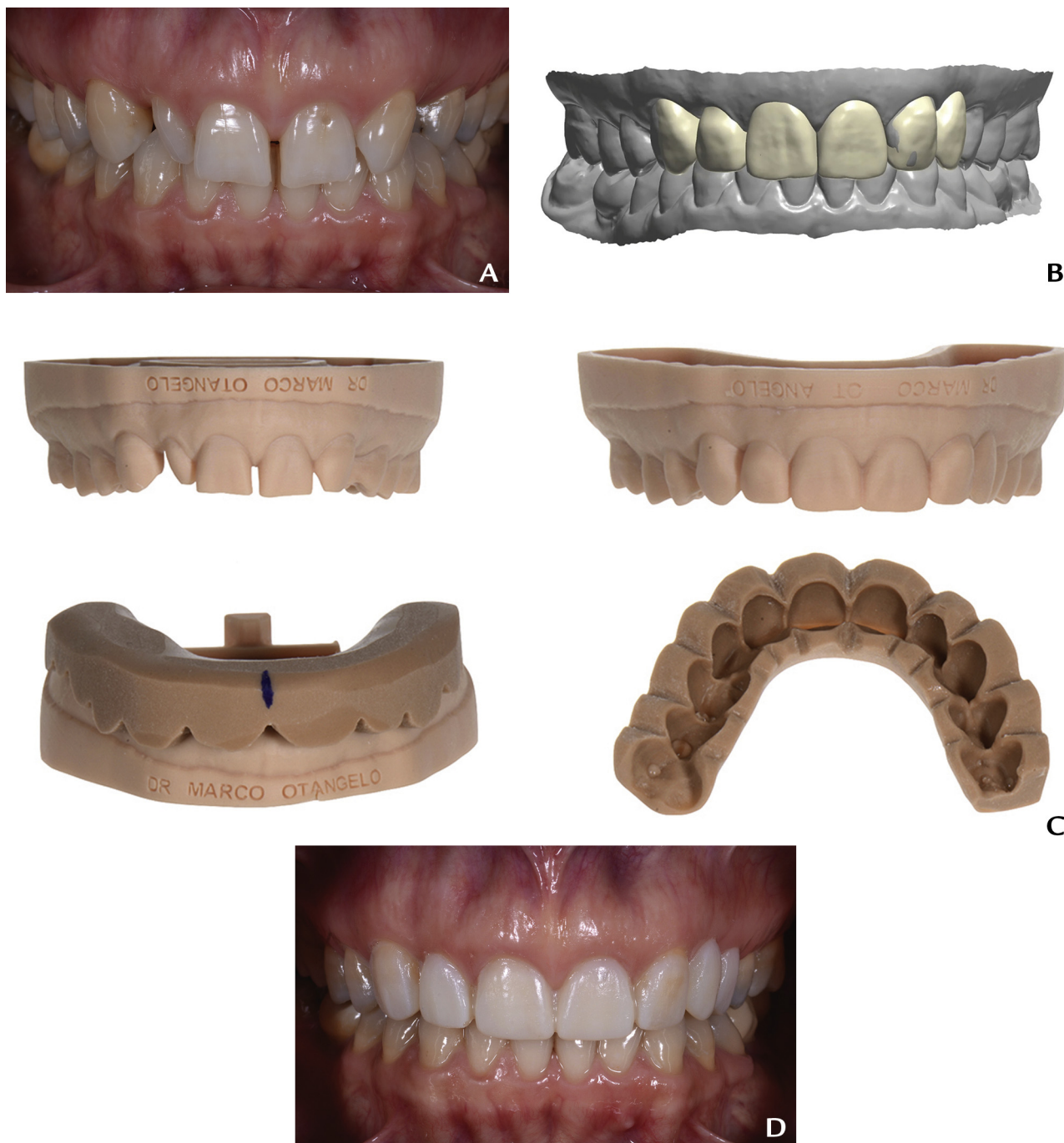

Figure 2. A, Clinical treatment that required additive approach. B, Digital trial restorations of additive clinical situation. C, Cast of initial situation, digital trial restorations, and silicone index. D, Resin trial restorations representing ideal situation to be scanned.

computer-aided design (CAD) laboratory software program (exocad DentalCAD; exocad GmbH, Dental Wings Dwo; Dental Wings Inc), which allows superimposition of the files and analysis of the space achieved through the “section” function. This procedure is equally effective, albeit more time consuming and less practical within the prosthetic workflow.

It is important to allow the most precise superimposition of the scans. For this reason, whenever possible, the procedure should start from a preoperative scan or a trial restoration scan. This file should then be copied and trimmed to eliminate other teeth that can be easily scanned and added to the copy of the original scan. This will accelerate the scanning process and improve the

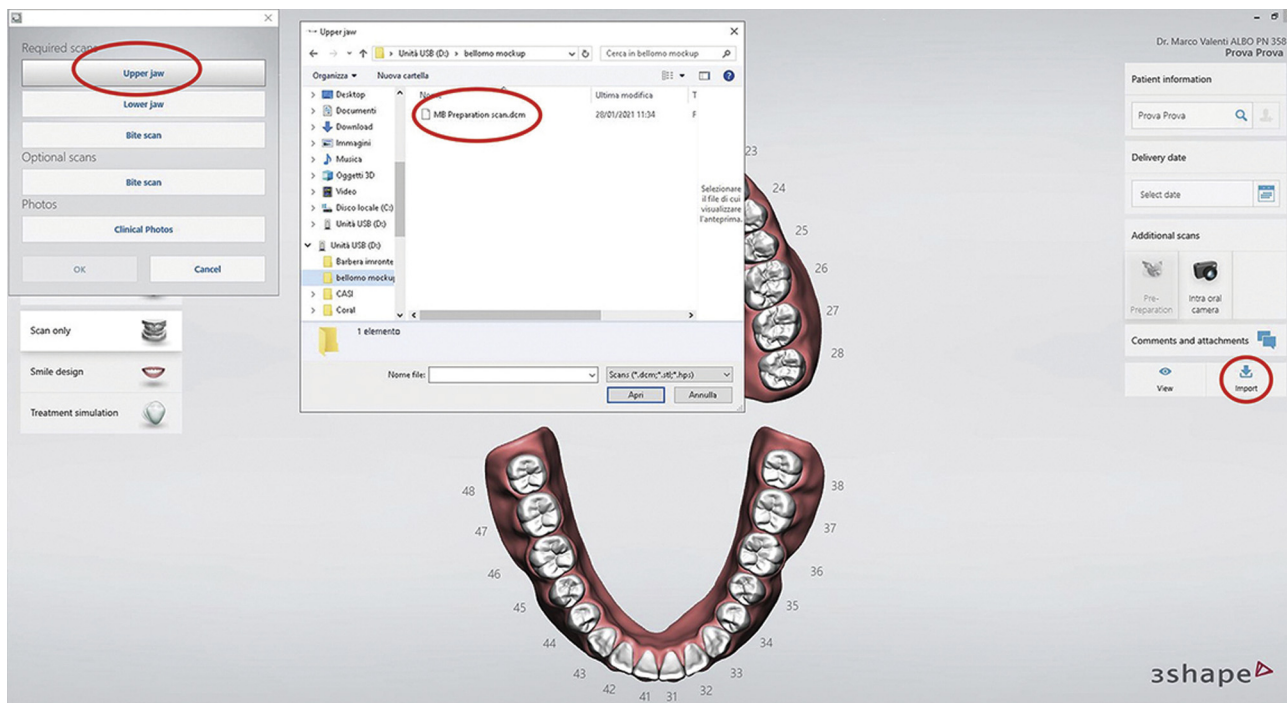


Figure 3. Procedure to import digital waxing file produced by dental laboratory technician if initial situation not ideal.

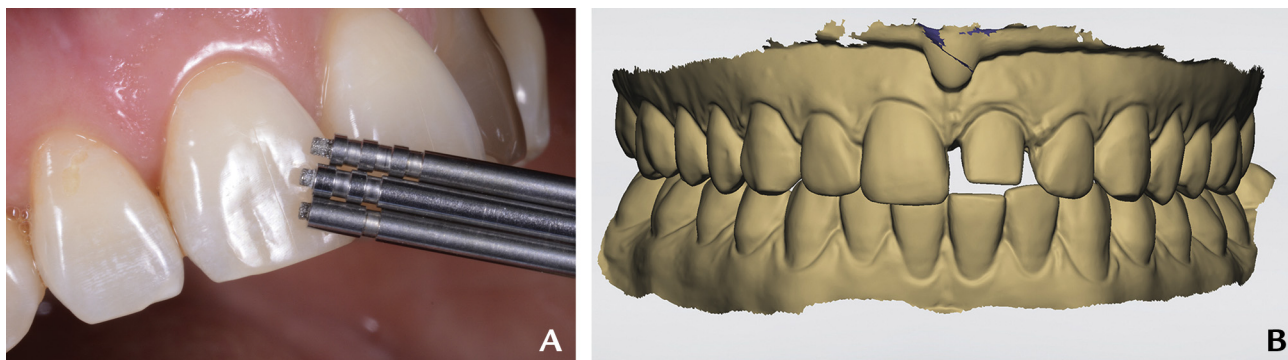


Figure 4. A, Calibrated rotary instruments to obtain controlled and homogeneous tooth reduction. B, Tooth prepared and scanned to start patient monitoring tool.

precision of the superimposition performed automatically by the software program. Overall, these tools enable ideal tooth preparation with the correct space for the restorative material used.

SUMMARY

A technique that allows clinicians and dental laboratory technicians to obtain valuable information regarding the preparation procedure is described. Following this protocol, the clinician can see where additional preparation is needed before commencing the procedure and can evaluate how much space has been given for the restorative material, improving the functional and esthetic outcomes of the restoration and tooth.

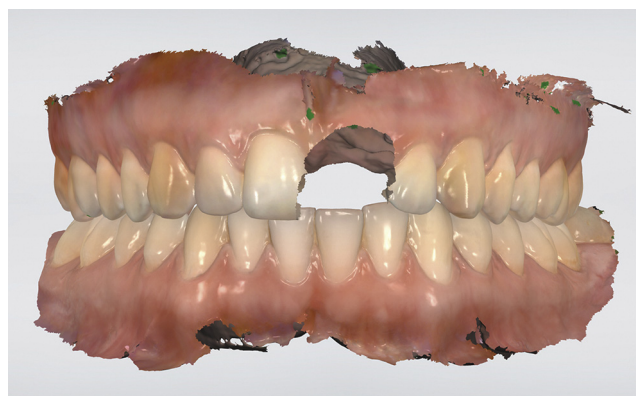

Figure 5. Tooth trimmed from Initial Scan after abutment preparation and before new scan made to start comparison.

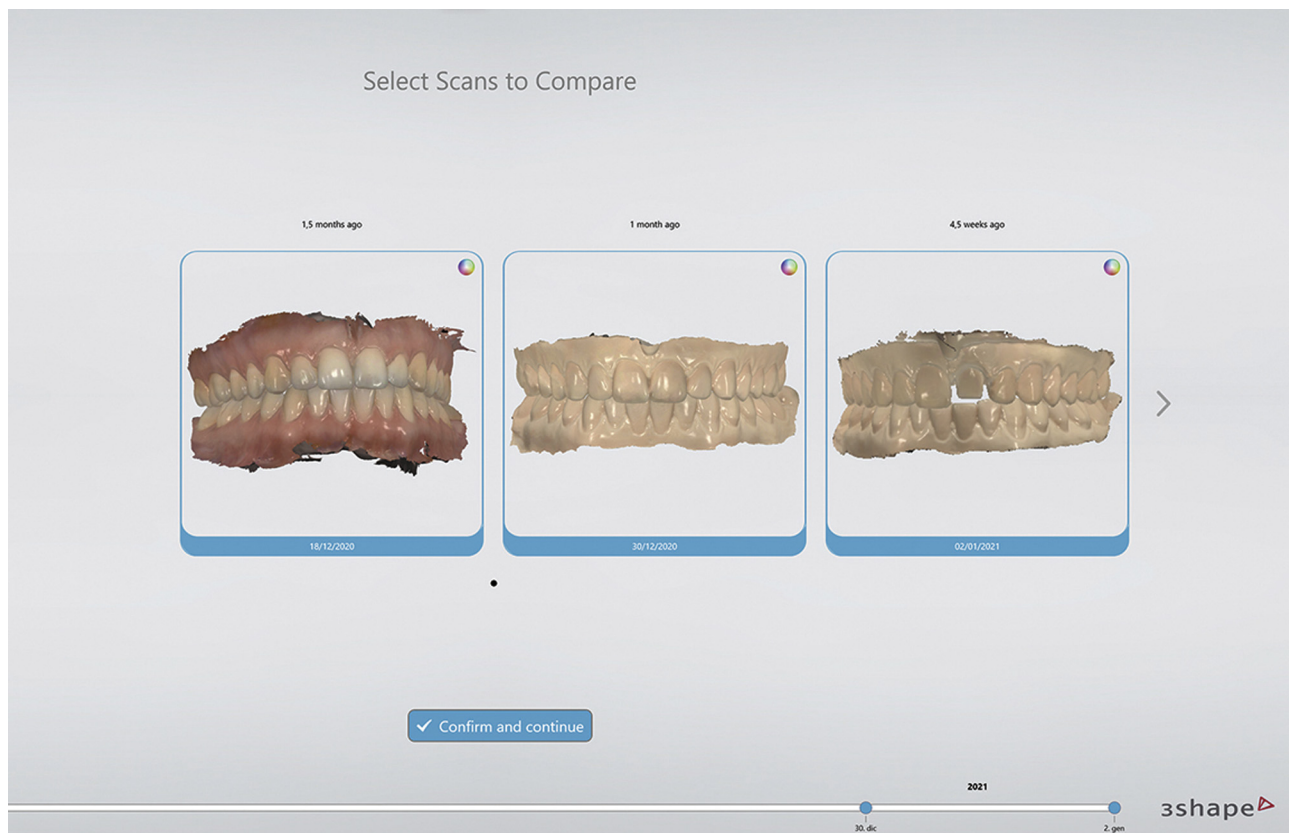


Figure 6. Patient monitoring window. Scans selected for comparison.

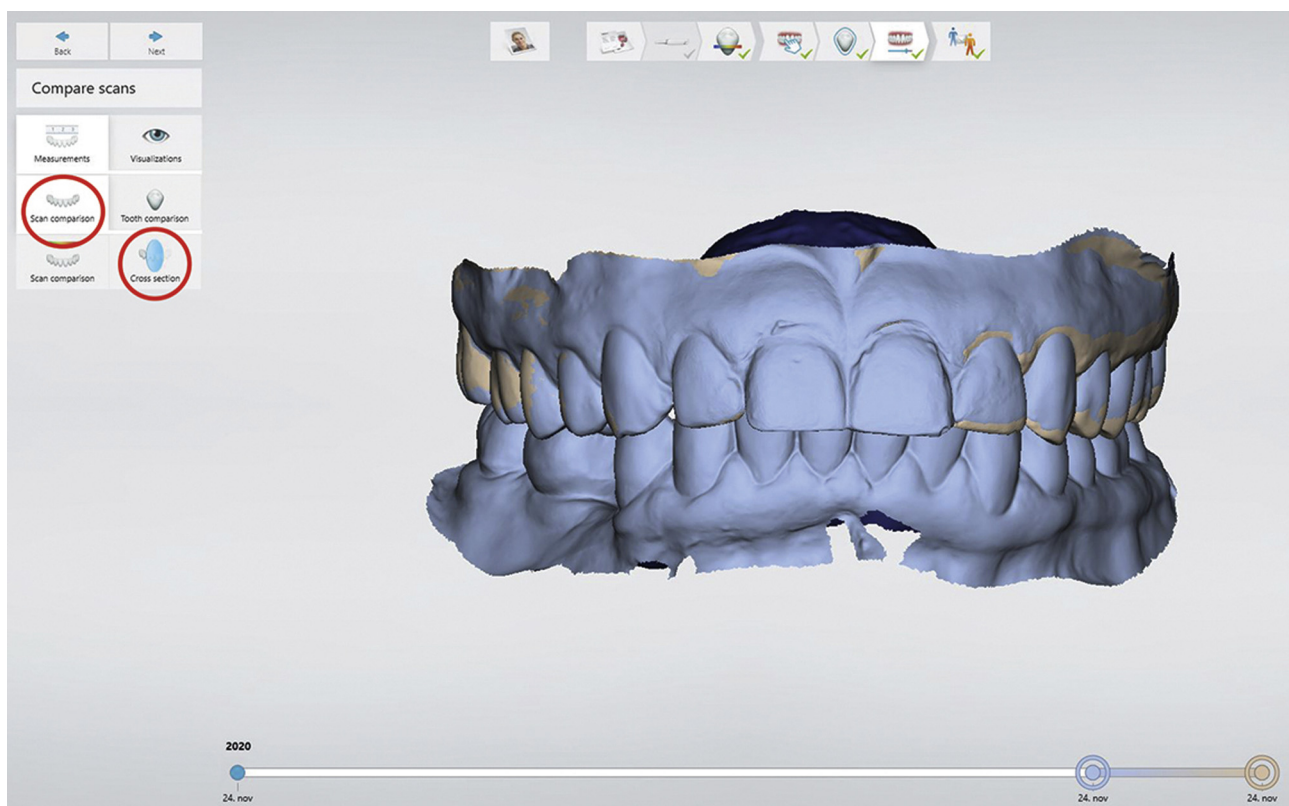


Figure 7. Scan comparison and cross-section tools on left menu.

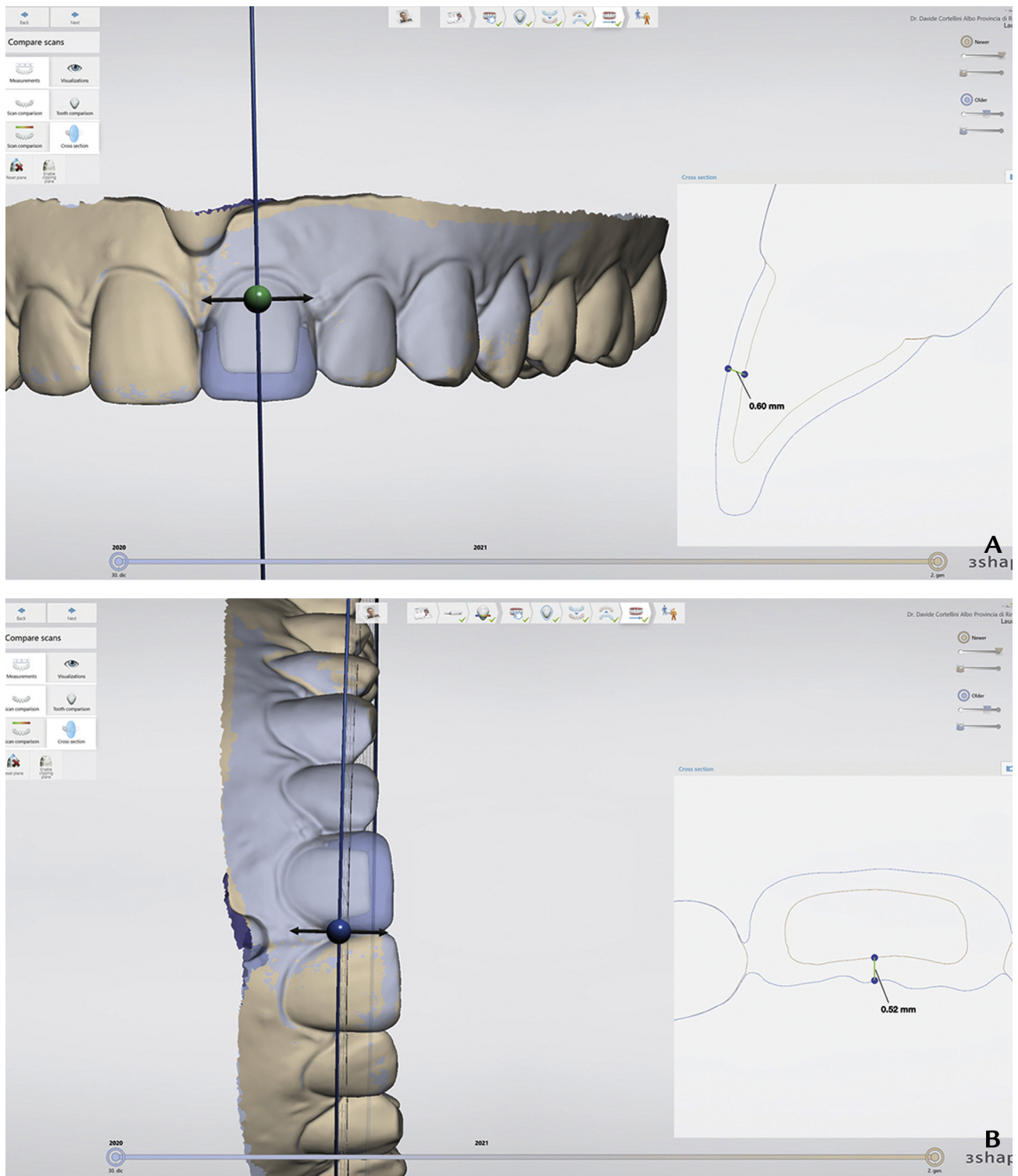


Figure 8. Thickness measurements. A, Longitudinal section. B, Transverse section.

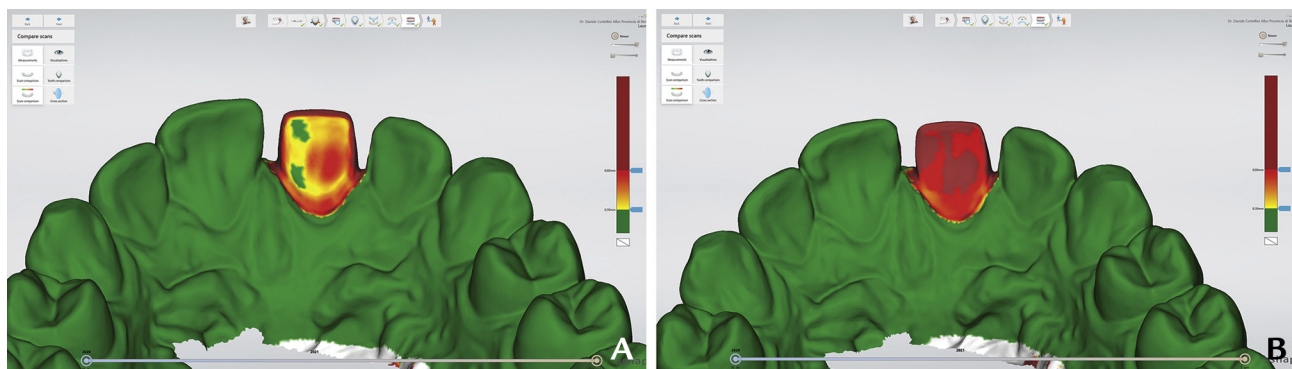


Figure 9. A, Activation of scan comparison in “patient monitoring” function reveals presence of small palatal areas lacking adequate thickness for restoration (green and yellow colors indicating average space of 0.0 to 0.3 mm). B, After correction by clinician, scan comparison shows different shades of red color indicating provided space, ranging between 0.5 and 0.8 mm, adequate for definitive ceramic crown.

REFERENCES

- Ram HK, Shah RJ, Agrawal HS. Evaluation of three different tooth preparation techniques for metal ceramic crowns by comparing preparation depths: An in vitro study. *J Indian Prosthodont Soc* 2015;15:162-7.
- Edelhoff D, Sorensen JA. Tooth structure removal associated with various preparation designs for anterior teeth. *J Prosthet Dent* 2002;87:503-9.
- Blair FM, Wassell RW, Steele JG. Crowns and other extra-coronal restorations: preparations for full veneer crowns. *Br Dent J* 2002;192:561-4. 567-71.
- Shillingberg HT, Hobo S, Whitsett L, Jacobi R, Brackett SE. *Fundamentals of fixed prosthodontics*. 3rd ed. Chicago: Quintessence; 1997.
- Goodacre CJ, Campagni WV, Aquilino SA. Tooth preparations for complete crowns: an art form based on scientific principles. *J Prosthet Dent* 2001;85:363-76.
- Cortellini D, Valenti M, Canale A. The metal-free approach to restorative treatment planning. *Eur J Esthet Dent* 2006;1:230-47.
- Donovan TE, Chee WW. Cervical margin design with contemporary esthetic restorations. *Dent Clin North Am* 2004;48:417-31.
- Valenti M, Valenti A. Retrospective survival analysis of 261 lithium disilicate crowns in a private general practice. *Quintessence Int* 2009;40:573-9.
- Cortellini D, Canale A. Bonding lithium disilicate ceramic to feather-edge tooth preparations: a minimally invasive treatment concept. *J Adhes Dent* 2012;14:7-10.
- Fradeani M, Barducci G, Bacherini L, Brennan M. Esthetic rehabilitation of a severely worn dentition with minimally invasive prosthetic procedures (MIPP). *Int J Periodontics Restorative Dent* 2012;32:135-47.
- Cortellini D, Canale A, Souza RO, Campos F, Lima JC, Ozcan M. Durability and Weibull characteristics of lithium disilicate crowns bonded on abutments with knife-edge and large chamfer finish lines after cyclic loading. *J Prosthodont* 2015;24:615-9.
- Schmitz JH, Valenti M. Interim restoration technique for gingival displacement with a feather-edge preparation design and digital scan. *J Prosthet Dent* 2020;123:580-3.
- Silva NR, Bonfante EA, Martins LM, Valverde GB, Thompson VP, Ferencz JL, et al. Reliability of reduced-thickness and thinly veneered lithium disilicate crowns. *J Dent Res* 2012;91:305-10.
- Valenti M, Valenti A. Retrospective survival analysis of 110 lithium disilicate crowns with feather-edge marginal preparation. *Int J Esthet Dent* 2015;10:246-57.
- Schmitz JH, Cortellini D, Granata S, Valenti M. Monolithic lithium disilicate complete single crowns with feather-edge preparation design in the posterior region: A multicentric retrospective study up to 12 years. *Quintessence Int* 2017;20:601-8.
- Xu X, Xie Q, Zhou Y, Wu L, Cao Y. Effect of a standardized training with digital evaluation on the improvement of prosthodontic faculty's performance in crown preparation: a pre-post design. *J Prosthodont* 2020;29:766-71.
- Winkelmeyer C, Wolfart S, Marotti J. Analysis of tooth preparations for zirconia-based crowns and fixed dental prostheses using stereolithography data sets. *J Prosthet Dent* 2016;116:783-9.
- Boening KW, Kaestner KI, Luthardt RG, Walter MH. Burs with guide pins for standardized tooth preparation. *Quintessence Int* 2001;32:191-7.
- Magne P, Belser UC. Novel porcelain laminate preparation approach driven by a diagnostic mock-up. *J Esthet Restor Dent* 2004;16:7-16.
- Gurreea J, Bruguera A. Wax-up and mock-up. A guide for anterior periodontal and restorative treatments. *Int J Esthet Dent* 2014;9:146-62.
- Edelhoff D, Ahlers MO. Occlusal onlays as a modern treatment concept for the reconstruction of severely worn occlusal surfaces. *Quintessence Int* 2018;49:521-33.
- Li ZY, Bai HF, Zhao YJ, Wang Y, Ye HQ, Sun YC. 3D evaluation of accuracy of tooth preparation for laminate veneers assisted by rigid constraint guides prepared by selective laser melting. *Chin J Dent Res* 2020;23:183-9.
- Peng M, Li C, Huang C, Liang S. Digital technologies to facilitate minimally invasive rehabilitation of a severely worn dentition: A dental technique. *J Prosthet Dent* 17 August 2020. <http://doi.org/10.1016/j.prosdent.2020.05.012>. Epub ahead of print.
- Taha Y, Raslan F, Ali A, Roig M. Guided tooth preparation device fabricated with a complete digital workflow: A dental technique. *J Prosthet Dent* 2021;125:221.e1-4.
- Oh KC, Kim JH. Digital preparation-evaluation tool. *J Prosthet Dent* 2020;124:816-7.
- Kang HY, Lee H, Chae YK, Hong SJ, Jeong YY, Lee KE, et al. Feasibility of 3-dimensional visual guides for preparing pediatric zirconia crowns: an in vitro study. *Int J Environ Res Public Health* 2020;17:5732.
- Lee H, Fehmer V, Kwon KR, Burkhardt F, Pae A, Sailer I. Virtual diagnostics and guided tooth preparation for the minimally invasive rehabilitation of a patient with extensive tooth wear: A validation of a digital workflow. *J Prosthet Dent* 2020;123:20-6.
- Leoney KS. Hinged single piece putty index for preclinical demonstration of tooth preparation for fixed partial dentures and crowns. *J Clin Diag Res* 2015;9:ZC09-12.

Corresponding author:

Dr Marco Valenti
Via G. B. Damiani
5, 33170 Pordenone
ITALY
Email: marco@studiodenticovalenti.com

CRediT authorship contribution statement

Marco Valenti: Conceptualization, Methodology, Writing - original draft, Visualization. **Johannes H. Schmitz:** Writing - original draft, Writing - review & editing. **Daive Cortellini:** Writing - original draft, Writing - review & editing. **Alessandro Valenti:** Writing - original draft, Writing - review & editing. **Angelo Canale:** Conceptualization, Methodology.

Copyright © 2021 by the Editorial Council for *The Journal of Prosthetic Dentistry*.
<https://doi.org/10.1016/j.prosdent.2021.04.017>