

The Effectiveness of Waist-Shaped and Straight-Shaped Interdental Brushes in Cleaning Implant Overdenture Attachments: A Self-Controlled Clinical Trial

Qiuwen Chen, DDS, PhD†
 Yanjun Ge, DDS, PhD†
 Jinyou Chai, DDS, PhD
 Hailan Feng, DDS, PhD
 Jianzhang Liu, DDS, PhD*‡
 Shaoxia Pan, DDS, PhD*‡

Elderly patients often find it challenging to remove plaque accumulated on the attachments of implant overdentures (IODs) using conventional cleaning instruments. Further, excessive plaque accumulation can lead to peri-implant diseases and occasionally to respiratory diseases. Therefore, here, we aimed to compare the effectiveness of waist-shaped interdental brushes (WIBs) with that of straight-shaped interdental brushes (SIBs) in plaque removal from the locator attachments of IODs. Twenty participants with 2 locator attachments retaining mandibular IODs participated in this study. After the baseline cleaning, the participants refrained from oral hygiene maintenance for 3 days. A dentist cleaned 1 of the attachments using the WIB and the other attachment using the SIB. The pre- and post-cleaning modified plaque index (mPLI) scores were recorded. After another 3 days free from oral hygiene maintenance, the trained participants repeated the same cleaning procedure using the WIB and SIB. Pre- and post-cleaning mPLI scores were recorded. Regardless of the type of brush used, the post-cleaning mPLI scores were lower than the pre-cleaning scores. After the cleaning procedure, the overall mean mPLI score was lower in the WIB group than in the SIB group. The post-cleaning mPLI scores at the line angles and on the axial surfaces of the attachments were also lower in the WIB group than in the SIB group. There was no difference in the cleaning effectiveness between the dentist and participants when they used the same type of interdental brush. The WIB was significantly more efficient in plaque removal than the SIB, especially at the line-angle sites.

Key Words: *interdental brush, implant overdentures, locator attachment, cleaning effectiveness, plaque removal, waist-shaped, straight-shaped*

INTRODUCTION

Mandibular edentulous patients often suffer from severe alveolar bone loss and are not always satisfied with using their conventional complete dentures. Compared with conventional complete dentures, implant overdentures (IODs) can improve denture retention, stability, and chewing efficiency. They can also result in greater patient satisfaction.¹⁻⁶ According to the McGill consensus and York consensus statements, the use of 2-implant-retained mandibular overdentures is recommended as the standard of care for edentulous patients.^{7,8}

However, accumulation of a plaque biofilm is a risk factor

for peri-implant mucositis and peri-implantitis.⁹⁻¹¹ Further, it has been found to be challenging for edentulous patients, most of whom are elderly, to control plaque accumulation on the IOD attachments owing to decreased hand dexterity. It is common to find that the implant attachments of elderly patients with IODs are often covered with abundant debris and, in some cases, calculus. Plaque that forms a biofilm on the attachments and neck of implants not only causes peri-implant disease but also results in the accumulation of pathogenic organisms, which may lead to the development of respiratory diseases from the perspective of systemic health.^{12,13} It is of the utmost importance for patients with IODs to remove plaque biofilm from around the attachments and to maintain the health status of the tissue surrounding their implants.¹⁴

Generally, aged individuals often have poor oral health, and most exhibit compromised capabilities in maintaining oral hygiene.¹⁵ Additionally, owing to the cognitive impairment and memory deficit that occur with age, elderly individuals may be unable to implement measures required to maintain oral hygiene in spite of receiving verbal instructions from doctors.^{15,16} Some geriatric diseases, such as arthritis and visual

Department of Prosthodontics, Peking University School and Hospital of Stomatology, National Clinical Research Center for Oral Diseases, National Engineering Laboratory for Digital and Material Technology of Stomatology, Beijing Key Laboratory of Digital Stomatology, Beijing, China.

* Corresponding author, e-mail: panshaoxia@vip.163.com

† These authors contributed equally as first authors.

‡ These authors contributed equally as corresponding authors.

<https://doi.org/10.1563/aaid-joi-D-19-00149>

deterioration, can also increase the difficulty associated with maintaining oral health in the elderly population.^{17,18} Therefore, clinicians are constantly searching for new instruments with better cleaning efficacy.

The waist-shaped interdental brush (WIB) (Circum dental brush, Top Caredent AG, Zurich, Switzerland) was designed to clean the interproximal spaces around periodontal-compromised dentition with improved efficacy.¹⁹ The main feature of the WIB is more volume at the base and tip of its brush. Compared with the use of the straight designed interdental brush (TePe Munhygienprodukt AB, Malmo, Sweden), application of the WIB was reported to result in significantly lower plaque index scores²⁰ resulting from the effective cleaning of the interproximal surfaces of the posterior teeth and implants, with a predominantly higher cleaning effect potentially achieved along the buccal and lingual line angles.¹⁹

However, few studies have addressed the efficiency of instruments in cleaning IOD attachments. Therefore, the purpose of this prospective randomized controlled clinical trial was to evaluate the cleaning effectiveness of the WIB and straight-shaped interdental brush (SIB) in removing plaque biofilm on IOD attachments, with the aim of collecting evidence to help provide appropriate instructions on hygiene maintenance to patients with IODs. The null hypothesis of this study was that there is no difference in cleaning effectiveness between the WIB and SIB.

MATERIALS AND METHODS

The study protocol was approved by the Institutional Review Board of Peking University School and Hospital of Stomatology. This study was undertaken with the understanding and written informed consent of each participant and was conducted in accordance with the 2013 World Medical Association's Declaration of Helsinki; further, the Ethical Principles for Medical Research Involving Human Subjects were implemented from the beginning to the end of this study. The clinical trial registry number is ChiCTR-INR-16008403.

Participant recruitment

Patients who received 2-implant-retained mandibular overdenture treatment from January to December 2016 were randomly selected and contacted to inquire whether they would like to participate in this study. Each participant had undergone a procedure involving the insertion of 2 implants in the interforaminal area, and all participants had received a mandibular IOD supported by 2 locator attachments 3 months after the surgery.

Inclusion and exclusion criteria

Patients were included in the study if all of the following conditions were met:

- All the surfaces of the implant abutments were intact and accessible to dental cleaning tools.
- The peri-implant tissue was in a healthy and stable condition with no bleeding on probing, and the probing depth was ≤ 3 mm.

- The participant was willing and able to accept the protocol and provide informed consent.

Patients were excluded from the study if they met any of the following criteria at baseline:

- Presence of peri-implant tissue swelling or suppuration around the implant
- Presence of uncontrolled general physical diseases related to peri-implant diseases (uncontrolled diabetes, nephropathy, general immunity defects)
- Presence of oral diseases other than peri-implantitis (oral candidiasis, xerostomia)
- Excessive cigarette consumption: heavy smokers (10 or more per day)
- Presence of other conditions that might influence the condition of the peri-implant soft tissue

Study procedures

This clinical trial was designed as a prospective randomized self-controlled split-mouth study.

The performance efficacy of the WIB (Circum Dental Brush No. 7, Top Caredent AG; \varnothing 8-5-8 mm) and SIB (Interdental Brush Pink, Top Caredent AG; \varnothing = 5 mm) were compared. During application, 2 interdental brushes of the same type were fixed onto a brush holder (CombiHalter Fingermodell, Top Caredent AG; Figure 1). Each participant was asked to attend 4 dental appointments. The workflow involved in each appointment is described in the following paragraphs, and the flow chart is presented in Figure 2.

During the first appointment, each participant received baseline peri-implant/abutment plaque, debris, and calculus cleaning treatment. Subsequently, the participants were asked to refrain from oral hygiene maintenance on the attachments for 3 days.

The second appointment was arranged 3 days later when biofilm had accumulated on the attachment. During this appointment, a trained dentist cleaned the attachments using the interdental brushes. Before the brushes were applied, an examiner registered the plaque scores²¹ at 8 sites around each attachment (mesiobuccal [MB], buccal [B], distobuccal [DB], distal [D], distolingual [DL], lingual [L], mesiolingual [ML], mesial [M]) as shown in Figure 3. This examiner was previously trained to record the modified plaque index (mPLI), and his mPLI recordings were calibrated by a professional periodontist in the case of 5 participants (25%) included in this study. Subsequently, he registered the mPLI scores for all the other participants.

Randomization was performed using the coin-tossing technique. One of the 2 attachments was randomly selected by the dentist and brushed with the SIB (SIB group), and the other attachment was brushed with the WIB (WIB group). Each interdental brush was applied 3 times in both the buccal-lingual direction and mesial-distal direction. After this, the examiner, who was blinded to the cleaning procedure, recorded the post-brushing mPLI scores.

At the end of this appointment, each participant was instructed on how to use the interdental brushes. The participants then returned home and cleaned the attachments

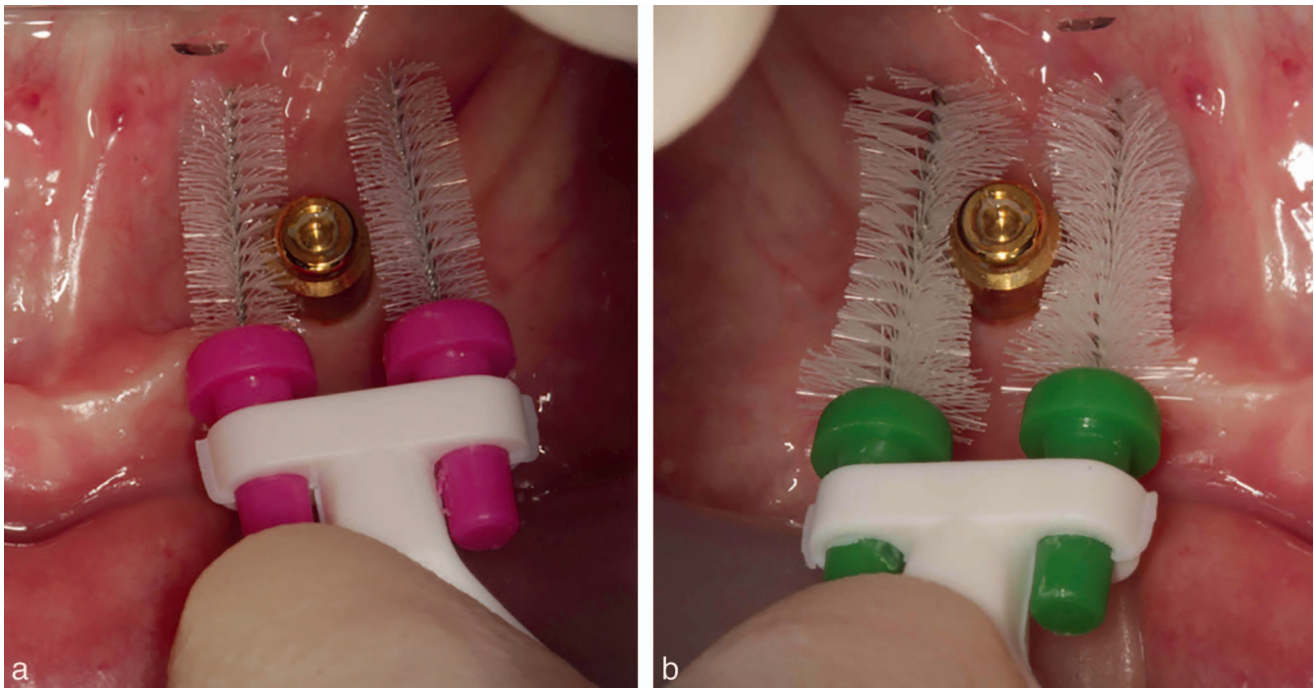


FIGURE 1. (a) Straight-shaped interdental brush with holder cleaning the locator. (b) Waist-shaped interdental brush with holder.

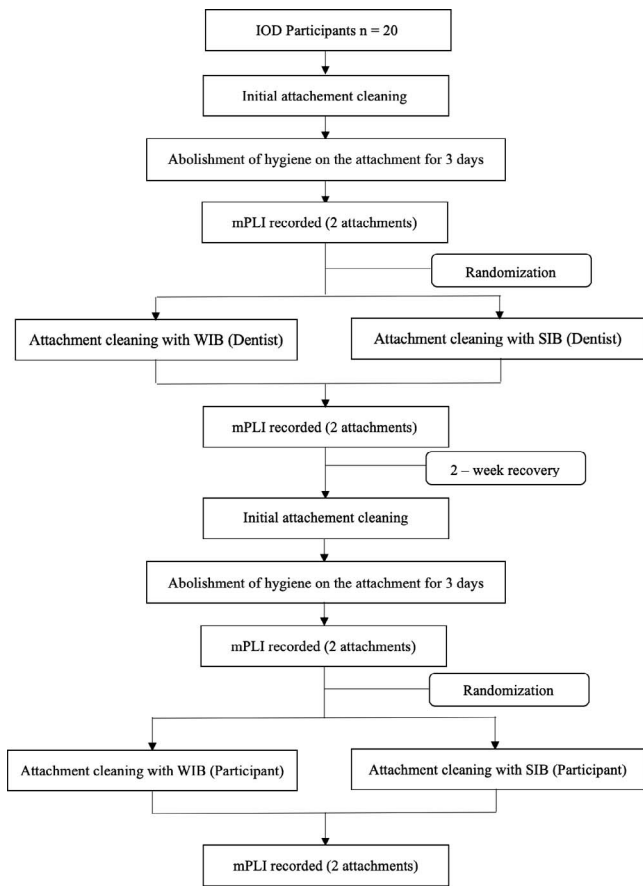


FIGURE 2. Study flow chart. IOD indicates implant overdentures; mPLI, modified plaque index; SIB, straight-shaped interdental brush; WIB, waist-shaped interdental brush.

using both the SIB and WIB by themselves for 2 weeks. They also performed their oral hygiene maintenance during this period.

The third appointment was scheduled 2 weeks after the second appointment, during which the basal areas of the attachments were cleaned by the dentist. Additionally, the dentist observed the participants while they used the interdental brushes and gave them additional instructions if necessary. Subsequently, the participants were again asked to refrain from oral hygiene maintenance of the attachments for 3 days.

The participants returned for the fourth appointment 3 days later. Plaque biofilm could be seen on the attachments. During this appointment, the examiner recorded the pre-cleaning mPLI scores. After this, under the supervision of the dentist, 1 of the locator attachments in each participant's mouth was randomly selected and was brushed by the participant with the SIB while the other was brushed with the WIB following the same protocol outlined during the second

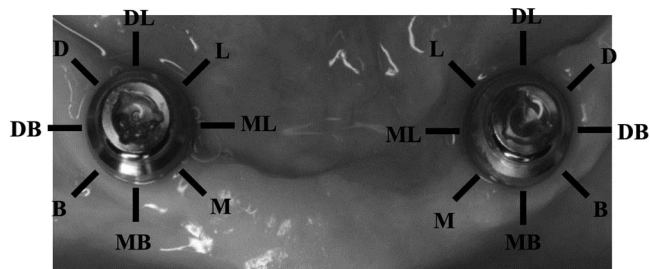


FIGURE 3. The 8 sites around the attachment, including the 4 line angles (distobuccal [DB], distolingual [DL], mesiobuccal [MB], mesiolingual [ML]) and 4 axial sites (buccal [B], distal [D], lingual [L], mesial [M]).

TABLE							
Mean (SD) of the plaque scores for all the assessed sites before and after the cleaning procedure*							
mPLI Score		Dentist Brushing			Participant Brushing		
		Overall	4 Line Angles	4 Axial Surfaces	Overall	4 Line Angles	4 Axial Surfaces
WIB	Before	2.59 (0.68)	2.63 (0.66)	2.56 (0.71)	2.65 (0.60)	2.66 (0.59)	2.64 (0.60)
	After	0.69 (0.72)	0.76 (0.73)	0.63 (0.70)	0.74 (0.70)	0.71 (0.62)	0.76 (0.77)
SIB	Before	2.62 (0.63)	2.64 (0.58)	2.60 (0.69)	2.73 (0.50)	2.76 (0.48)	2.70 (0.51)
	After	2.08 (0.86)	2.34 (0.81)	1.83 (0.84)	2.18 (0.77)	2.56 (0.57)	1.79 (0.74)

*mPLI indicates modified plaque index; SIB, straight-shaped interdental brush; WIB, waist-shaped interdental brush.

appointment. The examiner, who was blinded to the assignment of the cleaning tools and cleaning procedures, registered the post-brushing mPLI scores.

Clinical parameters

The mPLI scores were recorded at 8 sites (MB, B, DB, D, DL, L, ML, M; Figure 3) around the attachment based on the following scale²¹:

- 0: No plaque detected
- 1: Plaque could be detected by running a probe across the smooth marginal surface of the abutment and implant
- 2: Plaque observable to the naked eye
- 3: An abundant amount of plaque

Statistical analysis

A power analysis was performed to estimate the number of participants required to detect a difference of 0.2 in the mPLI score. The SD was estimated at 0.33,¹⁹ and a paired Student *t* test was performed owing to the split-mouth design of the study. Per the results, it was estimated that an ideal sample size of 14 individuals would be required to achieve 90% power at a 5% significance level. Six extra participants were included to compensate for possible dropouts.

Data were coded in Excel (Microsoft Excel for Mac v16.42, Redmond, Wash), and the statistical analyses were performed using the statistical SPSS software application (SPSS Statistics v20, IBM, Armonk, NY). A Student *t* test for paired samples was performed to compare the pre- and post-brushing mPLI scores. The level of statistical significance was set at $P < .01$. The frequency analysis results of individual mPLI scores of 0 and 1 versus 2 and 3 were compared before and after brushing. The statistical methodology was reviewed by an independent statistician.

RESULTS

Twenty participants were recruited for the study. The average age was 62.5 ± 9.58 years, with the participants ranging from 42 to 80 years old. Ten patients were men, and 10 were women. Each participant received 2-implant-retained IOD treatment in the lower jaw (Straumann AG, Basel, Switzerland or Bego, Bremen, Germany). All of the attachments used were locator attachments. Forty locator attachments were included in this

study, and mPLI scores were recorded at 320 sites around the attachments during each registration procedure.

Overall mean mPLI scores

The overall mean mPLI scores are shown in the Table. During the second appointment, the mean pre-brushing mPLI scores in the WIB and SIB groups were 2.59 (SD: 0.68) and 2.62 (SD: 0.63), respectively. After the dentist brushed the attachments, the mean mPLI scores significantly decreased to 0.69 (SD: 0.72) in the WIB group ($P < .001$) and 2.08 (SD: 0.86) in the SIB group ($P < .001$; Figure 4). After the dentist's intervention, the mean mPLI score in the WIB group was significantly lower than that in the SIB group ($P < .001$).

During the fourth appointment, the mean pre-brushing mPLI scores in the WIB and SIB groups were 2.65 (SD: 0.60) and 2.73 (SD: 0.50), respectively. After the participant brushed the attachments, the mean mPLI scores significantly decreased to 0.74 (SD: 0.70) in the WIB group ($P < .001$) and 2.18 (SD: 0.77) in

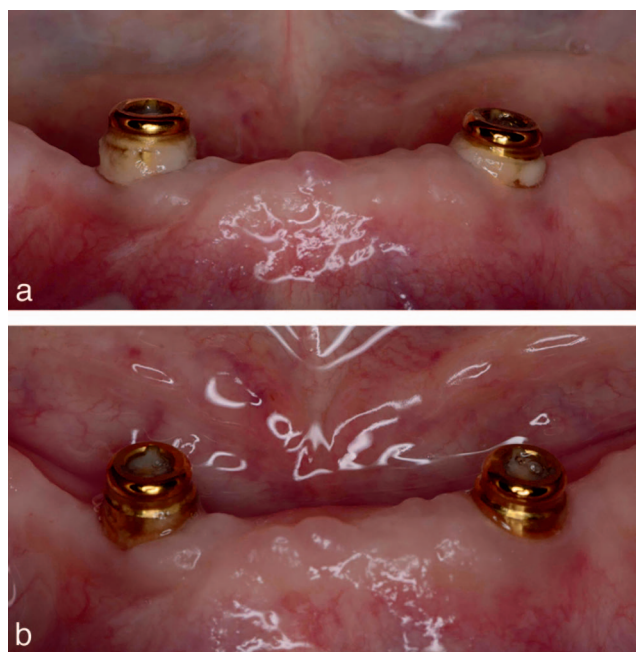


FIGURE 4. The plaque on the attachments before (a) and after (b) brushing (dentist brushing). The attachment on the right side was cleaned using the straight-shaped interdental brush, and the attachment on the left was cleaned using the waist-shaped interdental brush.

the SIB group ($P < .001$). After the participant's intervention, the mean mPLI score in the WIB group was significantly lower than that in the SIB group ($P < .001$).

There were no differences in the mean pre-brushing mPLI scores between the WIB and SIB groups during the second and fourth appointments. In both the WIB and SIB groups, when the post-brushing mPLI scores recorded during the second and fourth appointments were compared (dentist brushing versus participants brushing), no differences were detected (Table).

Mean mPLI scores at the axial surface sites

The mean mPLI scores at the axial surface sites (B, L, M, D) are shown in the Table. During the second appointment, the mean pre-brushing mPLI scores at the 4 axial surface sites in the WIB and SIB groups were 2.56 (SD: 0.71) and 2.60 (SD: 0.69), respectively. After the dentist brushed the attachments, the mean mPLI scores on the axial surfaces significantly decreased to 0.63 (SD: 0.70) in the WIB group ($P < .001$) and 1.83 (SD: 0.84) in the SIB group ($P < .001$). After the dentist's intervention, the mean mPLI score on the axial surfaces of the WIB group was significantly lower than that of the SIB group ($P < .001$). The results recorded during the fourth appointment (participant brushing) were similar to those from the second appointment (dentist brushing; Table).

The mean pre- and postintervention mPLI scores at the axial surface sites are presented in the Table. The WIB resulted in significantly higher plaque removal effectiveness on the axial surface of the locator attachments than the SIB ($P < .001$). Regardless of whether the dentist or participant cleaned the attachment, no differences were observed in the findings.

Mean mPLI scores at the line-angle sites

The mean mPLI scores at the line-angle sites (MB, DB, ML) are shown in the Table. During the second appointment, the mean pre-brushing mPLI scores at the 4 line angles in the WIB and SIB groups were 2.63 (SD: 0.66) and 2.64 (SD: 0.58), respectively. After the dentist brushed the attachments, the mean mPLI scores at the 4 line angles significantly decreased to 0.76 (SD: 0.73) in the WIB group ($P < .001$). However, in the SIB group, there were no significant changes in the mPLI scores even though the mean score decreased to 2.34 (SD: 0.81; $P > .05$). After the dentist's intervention, the mean mPLI score at the 4 line angles in the WIB group was significantly lower than that in the SIB group ($P < .001$).

During the fourth appointment (participant brushing), the results were similar to those recorded in the second appointment (dentist brushing). The mean pre- and post-intervention mPLI scores at the 4 line-angles are presented in the Table. The WIB resulted in significantly higher plaque removal efficiency at the 4 line angles of the locator attachment than the SIB ($P < .001$).

Frequency analyses of sites with mPLI scores of 0 or 1 versus 2 or 3

When both the dentist and participants performed the brushing procedure, a significant improvement was detected in the plaque score categories at the 320 sites after the application of both types of interdental brushes ($P < .05$).

However, it was indicated that the number of sites that recorded mPLI category changes from 2 or 3 to 0 or 1 was much higher when the WIB rather than the SIB was used. The changes in plaque score distribution frequency after the intervention by the dentist and participant are presented in Figure 5.

When only the 4 line angles were considered, the distribution of mPLI scores in the WIB and SIB groups was comparable to that before the intervention. However, after the application of the SIB, the distribution of mPLI scores (2 or 3 versus 0 or 1) did not significantly change, whereas after application of the WIB, the number of sites with mPLI scores of 0 or 1 significantly increased ($P < .01$). The changes in plaque score distribution frequency at the 4 line angles after the dentist's or participants' intervention are presented in Figure 6.

DISCUSSION

This study evaluated the effectiveness of 2 types of interdental brushes in plaque cleaning from the locator attachments of patients with IODs. The results indicate that both types of interdental brushes were effective in plaque removal from the locator attachments. However, the plaque removal effectiveness of the WIB from the mandibular IOD attachments (locator) was significantly higher than that of the SIB.

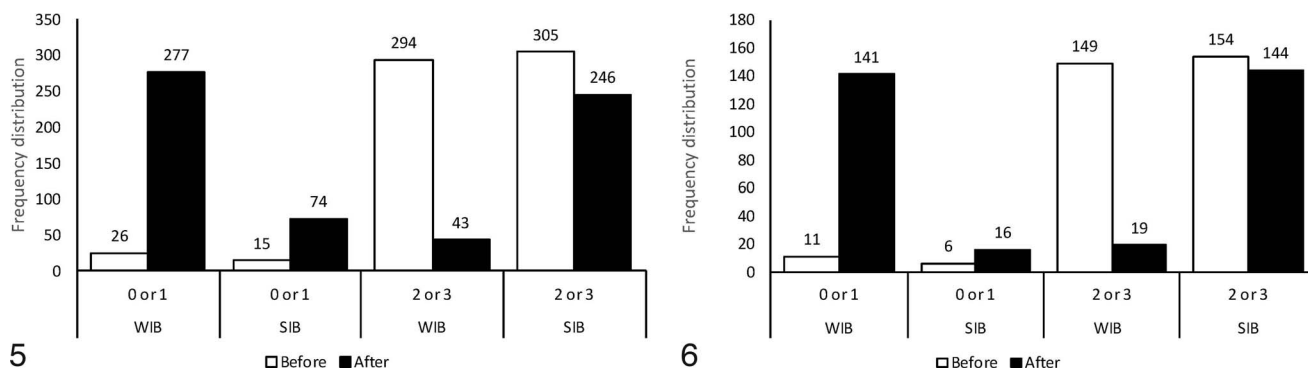
Study design

This clinical trial was designed as a randomized controlled single-blind split-mouth study. This design eliminated many confounding factors that could potentially introduce bias into the results.²² The examiner was blinded to the types of plaque control devices that were used by the trained dentist and participants. The split-mouth design warranted that the comparison between the plaque cleaning effectiveness of the 2 tested interdental brushes could be performed in exactly the same environment, thereby avoiding the effects of the differences in the plaque index and hand dexterity among the different participants. Thus, the noise associated with the clinical trial could be reduced, which allowed us to conduct a more powerful statistical test.²²

Plaque removal effectiveness of the WIB and SIB

Interdental brushes have been proven to be more effective in plaque removal within sufficiently exposed interproximal spaces compared with dental floss and toothpicks.²³ Rosing and colleagues²⁴ conducted a comparative study among 50 individuals and found that interdental toothbrushes, regardless of their shape (conical or cylindrical), are more effective in interdental supragingival plaque removal than dental floss.

In our study, both the WIB and SIB were effective in plaque removal, and significant differences were found between the pre- and post-brushing overall mean mPLI scores after the use of both brushes. This is consistent with the findings of previous studies on the effectiveness of interdental brushes in interproximal cleaning.²⁴⁻²⁶ Moreover, our study also demonstrated that the overall plaque removal effectiveness of the WIB was significantly higher than that of the SIB, which is in accordance with the findings of a previous study in which the plaque



FIGURES 5 AND 6. **FIGURE 5.** Plaque score distribution (modified plaque index [mPLI] = 0 or 1 versus mPLI = 2 or 3) before and after the dentist's or participants' intervention with the waist-shaped interdental brush (WIB) and straight-shaped interdental brush (SIB). **FIGURE 6.** Plaque score distribution (modified plaque index 0 or 1 versus 2 or 3) at the 4 line-angle sites before and after brushing using the waist-shaped interdental brush (WIB) and straight-shaped interdental brush (SIB), respectively.

removal effectiveness of the same WIB was compared with that of an SIB.¹⁹

When the 8 sites around the attachment were evaluated separately, the effectiveness of plaque removal in the WIB group was significantly superior to that in the SIB group at all 4 line angles. This was similar to the results of a previous study conducted by Chongcharoen et al.¹⁹ In this previous study, application of a WIB resulted in significantly lower plaque index scores on natural teeth and implants than those recorded with the use of an SIB, and this result was predominantly due to the higher cleaning effect of the WIB at the buccal and lingual line angles. The explanation behind this finding was that when the WIB, characterized by a larger diameter at the base and tip, was passed through the proximal contact, it resulted in more friction being applied onto the teeth or prostheses at the line angles. We could also justify this in our study by the fact that the transverse sections of the attachments were usually round, and the WIB had a waist-shaped design, with a larger diameter at the base and tip as well as a narrower middle section. After being fixed onto the holder, the brushes acted like 2 arms that hugged the locator attachment, and hence, the contact area between the bristles and attachment was larger compared with the contact area when the SIB was used, thereby resulting in more friction and in cleaning away more plaque at the line-angle sites. In other words, the SIB was not as effective as the WIB in cleaning the biofilm from the line-angle sites because a much smaller contact area was produced with the attachment. As a result, when equal brush strokes were applied, more plaque could be removed by the WIB, and therefore, the effectiveness of the WIB was found to be greater.

In addition to the aforementioned findings, our study also demonstrated that the plaque removal effectiveness on the 4 axial surfaces observed in the WIB group was significantly better than that in the SIB group. This is different from the findings of Chongcharoen et al,¹⁹ in which biofilm reduction was not observed at the buccal sites after use of interdental brushes. This difference was mainly due to the difference in structure between locator attachments and natural dentition/ fixed implant prostheses; specifically, the interdental brush could easily reach all the surfaces of the locator attachment of the IOD-wearing patients with no limitations with respect to

stroke direction and, thus, could result in equal cleaning effectiveness on all the surfaces of the attachment.

There was a significant difference in the frequency distribution between the group with mPLI scores of 0 or 1 and those with mPLI scores of 2 or 3 before and after the use of the interdental brushes. The mPLI scores recorded at a significantly larger number of sites shifted from 2 or 3 to 0 or 1 in the WIB group compared with the SIB group (χ^2 , $P < .01$), thereby suggesting that the WIB was more efficient in biofilm cleaning than the SIB.

Capability of elderly IOD users in performing peri-implant plaque control practices and choice of cleaning instrument

No significant differences were detected between the mean post-brushing mPLI scores obtained when the dentist or participants carried out the brushing. This indicated that with the help of professional instruction and training, the patients were able to learn the skills required to use an interdental brush to properly remove the biofilm from the locator. In the present study, we prescribed strict adherence to the standard cleaning procedure that involved using the brush holder (HC Combi-Halter Fingermodell, Top Caredent A, Zurich, Switzerland) to hold 2 interdental brushes and then brushing the attachments 3 times horizontally in both the buccal-lingual direction and mesial-distal direction. Participants were asked to practice the brushing movement under the guidance and supervision of the dentist, and this strategy was proven to be successful. We found that the participants were able to perform as effectively as the dentist.

Studies that have investigated cleaning instruments and their efficacy in plaque control on IOD attachments are scarce. We found only 1 report that compared the clinical effectiveness of a powered toothbrush with that of a manual soft toothbrush in the control of supragingival plaque and soft tissue inflammation around mandibular IODs.²⁷ In this previous study, after receiving a detailed video and written instructions, the patients cleaned their 2 single-standing mandibular IOD attachments twice daily for 6 weeks using the toothbrush being tested, and the results revealed that only 15% of the sites in the manual toothbrush group and 20% of the sites in the

powered toothbrush group exhibited improved plaque scores, while the condition of the other sites remained the same or even worsened. However, the 2 types of toothbrushes used in the study were the same as those used for brushing natural dentition; therefore, it is a strong possibility that when the patients attempted to brush the attachments with these toothbrushes, it was difficult to direct the tip of the bristles to reach the gingival one-third of the attachment. On the contrary, in our study, the interdental brushes were designed such that the tip of every bristle could touch the surface of the attachment from a perpendicular direction and, thus, could produce adequate friction to efficiently remove the biofilm. Even though edentulous elderly individuals were considered to be compromised due to advanced age, impaired manual skills, and reduced visual capacity,²⁷ our study still managed to prove that they could perform well in implant attachment plaque control when user-friendly cleaning aids were available. A deliberate choice of instrument is always important in periodontal and peri-implant maintenance, especially for the elderly population.

A person's long-term maintenance of oral health is related to the long-term biological stability of implants and promotes the prevention of biological inflammation.^{28,29} It has been reported that repetitive and visual hygiene instructions, such as instructions outlined in brochures, are required to improve the oral hygiene maintenance skills of the elderly.³⁰ Providing elderly patients with a more efficient instrument is another way of improving the plaque removal effect. Therefore, the WIB is obviously a more effective instrument that can help elderly IOD wearers to efficiently maintain their oral hygiene.

However, we should also bear in mind that due to cognitive impairment, memory decline, and arthritis, elderly patients may not be able to completely execute the instructions provided via oral hygiene maintenance guidance, even when dentists have provided instructions visually and tautologically.^{15,16} Although our study has demonstrated that the participants could use the interdental brushes skillfully after receiving instructions and training, we are still far from being able to draw conclusions regarding the long-term self-maintenance of oral health among elderly edentulous IOD wearers.

Plaque control among different attachment designs

Both splinted (bar) and single-standing attachments (locator, telescopic crown) can be used to retain IOD. It has been demonstrated that hygiene maintenance is more complicated around bars than around locator and telescopic crowns,^{31,32} and annually higher plaque index and calculus index scores have been observed in relation to the bar rather than to the telescopic attachments.³³ However, plaque-cleaning instruments were not mentioned in these studies. On using the WIB tested in the present study, limitations with respect to accessing all the surfaces of the abutment of bar attachments encountered with most cleaning aids can be overcome. The plaque control efficacy of the WIB in cleaning IOD bar attachments should be investigated in the future.

A triangular hole was designed on top of the Locator abutment, inside which plaque gets easily accumulated. In this study, the plaque removal in this undercut area was not investigated. However, this area should be included in the

routine cleaning procedure. Even though the biofilm in this area does not directly make contact with the peri-implant soft tissue, the accumulation of plaque or formation of calculus within it would still affect the proper sitting of the overdenture and would deform the nylon cap.

Study limitations

This study has several limitations. First, the coin-flipping method was used to randomly select a locator abutment to be brushed with the SIB; the other was brushed with the WIB. This method may not generate random results and, therefore, may influence the solidity of the results. Second, a convenience sampling technique was used to recruit participants for this study; therefore, our results might be vulnerable to selection bias and uncontrolled intervening variables. Patients who were self-disciplined with regard to health issues would be more prone to participate in the study. Consequently, the characteristics of our study participants might not represent those of a randomly selected sample from the general edentulous IOD-wearing population. Moreover, the participants who completed the clinical trial by attending all 4 appointments might have been individuals who already practiced effective maintenance techniques for their overdenture attachment, and this could lead to achieving better results than those that could have been achieved in the general edentulous population. These limitations need to be recognized, and the results and conclusions should be carefully interpreted for use in clinical situations. In a real-world clinical setting, patients may have smoking habits and systemic diseases, such as diabetes, and these are all risk factors that make it more difficult to maintain peri-implant health.

This study was a self-controlled randomized clinical trial, and a total of 20 participants were sufficient to provide enough power for the analysis. Future studies should adopt a randomization method, such as the random number table technique, to eliminate bias that might be introduced by the use of the coin-flipping method. For a more advanced approach, a stratified randomization method could be used in future studies to further investigate the influence of age. Convenience sampling and other techniques that could result in volunteer bias should be avoided in future studies.

CONCLUSIONS

Both the WIB and SIB were effective in plaque removal from single standing attachments (Locator) retaining mandibular IODs. However, the results of this study demonstrate that the WIB was more effective in plaque removal from the locator attachment, especially in the line-angle area, than the SIB.

ABBREVIATIONS

B: buccal
D: distal
DB: distobuccal
DL: distolingual
IOD: implant overdenture

L: lingual
 M: mesial
 MB: mesiobuccal
 ML: mesiolingual
 mPLI: modified plaque index
 SIB: straight-shaped interdental brush
 WIB: waist-shaped interdental brush

ACKNOWLEDGMENT

The authors express their gratitude to the independent statistician, Professor Liang-ping Hu (Graduate School, Academy of Military Sciences PLA China, Beijing, China), for reviewing the methodology of the statistical analysis of this clinical research paper.

NOTE

The authors declare that they have no conflict of interest.

REFERENCES

- Heydecke G, Locker D, Awad MA, Lund JP, and Feine JS. Oral and general health-related quality of life with conventional and implant dentures. *Community Dent Oral Epidemiol* 2003;31:161–168.
- Thomason JM, Lund JP, Chehade A, Feine JS. Patient satisfaction with mandibular implant overdentures and conventional dentures 6 months after delivery. *Int J Prosthodont*. 2003;16:467–473.
- Meijer HJ, Raghoebar JM, Van 't Hof MA. Comparison of implant-retained mandibular overdentures and conventional complete dentures: a 10-year prospective study of clinical aspects and patient satisfaction. *Int J Oral Maxillofac Implants*. 2003;18:879–885.
- Awad MA, Lund JP, Shapiro SH, et al. Oral health status and treatment satisfaction with mandibular implant overdentures and conventional dentures: a randomized clinical trial in a senior population. *Int J Prosthodont*. 2003;16:390–396.
- Zitzmann NU, Sendi P, Marinello CP. An economic evaluation of implant treatment in edentulous patients—preliminary results. *Int J Prosthodont*. 2005;18:20–27.
- Attard NJ, Zarb GA. Long-term treatment outcomes in edentulous patients with implant overdentures: the Toronto study. *Int J Prosthodont*. 2004;17:425–433.
- Feine JS, Carlsson GE, Awad MA, et al. The McGill Consensus Statement on Overdentures. Montreal, Quebec, Canada. May 24–25, 2002. *Int J Prosthodont* 2002;15:413–414.
- Thomason JM, Kelly SA, Bendkowski A, Ellis JS. Two implant retained overdentures—a review of the literature supporting the McGill and York consensus statements. *J Dent*. 2012;40:22–34.
- Ferreira SD, Silva GL, Cortelli JR, Costa JE, Costa FO. Prevalence and risk variables for peri-implant disease in Brazilian subjects. *J Clin Periodontol*. 2006;33:929–935.
- Roos-Jansaker AM, Renvert H, Lindahl C, Renvert S. Nine- to fourteen-year follow-up of implant treatment. Part III: factors associated with peri-implant lesions. *J Clin Periodontol*. 2006;33:296–301.
- Costa FO, Takenaka-Martinez S, Cota LO, Ferreira SD, Silva GL, Costa JE. Peri-implant disease in subjects with and without preventive maintenance: a 5-year follow-up. *J Clin Periodontol*. 2012;39:173–181.
- Sumi Y, Kagami H, Ohtsuka Y, Kakinoki Y, Haruguchi Y, Miyamoto H. High correlation between the bacterial species in denture plaque and pharyngeal microflora. *Gerodontology*. 2003;20:84–87.
- Scannapieco FA. Pneumonia in nonambulatory patients. The role of oral bacteria and oral hygiene. *J Am Dent Assoc*. 2006;137(suppl):21S–25S.
- Covani U, Marconcini S, Crespi R, Barone A. Bacterial plaque colonization around dental implant surfaces. *Implant Dent*. 2006;15:298–304.
- Kulak-Ozkan Y, Kazazoglu E, Arikani A. Oral hygiene habits, denture cleanliness, presence of yeasts and stomatitis in elderly people. *J Oral Rehabil*. 2002;29:300–304.
- Zakrzewska JM, Leeson RM, Mcluskey M, Vickers M. The development of patient information leaflets. Care of the mouth after radiotherapy. *Gerodontology*. 1997;14:48–53.
- Quillen DA. Common causes of vision loss in elderly patients. *Am Fam Physician*. 1999;60:99–108.
- Wolff B, Berger T, Frese C, et al. Oral status in patients with early rheumatoid arthritis: a prospective, case-control study. *Rheumatology (Oxford)*. 2014;53:526–531.
- Chongcharoen N, Lulic M, Lang NP. Effectiveness of different interdental brushes on cleaning the interproximal surfaces of teeth and implants: a randomized controlled, double-blind cross-over study. *Clin Oral Implants Res*. 2012;23:635–640.
- Loe H, Silness J. Periodontal disease in pregnancy. I. Prevalence and severity. *Acta Odontol Scand*. 1963;21:533–551.
- Mombelli A, van Oosten MA, Schurch EJ, Land NP. The microbiota associated with successful or failing osseointegrated titanium implants. *Oral Microbiol Immunol*. 1987;2:145–151.
- Hujoel PP, DeRouen TA. Validity issues in split-mouth trials. *J Clin Periodontol*. 1992;19:625–627.
- Gjeramo P, Flotra L. The effect of different methods of interdental cleansing. *J Periodontol Res*. 1970;5:230–236.
- Rösing CK, Daut FA, Festugatto FE, Oppermann RV. Efficacy of interdental plaque control aids in periodontal maintenance patients: a comparative study. *Oral Health Prev Dent*. 2006;4:99–103.
- Yost KG, Mallatt ME, Liebman J. Interproximal gingivitis and plaque reduction by four interdental products. *J Clin Dent*. 2006;17:79–83.
- Jackson MA, Kellett M, Worthington HV, Clerehugh V. Comparison of interdental cleaning methods: a randomized controlled trial. *J Periodontol*. 2006;77:1421–1429.
- Tawse-Smith A, Duncan WJ, Payne AG, Thomson WM, Wennstrom JL. Relative effectiveness of powered and manual toothbrushes in elderly patients with implant-supported mandibular overdentures. *J Clin Periodontol*. 2002;29:275–280.
- Silverstein LH, Kurtzman GM. Oral hygiene and maintenance of dental implants. *Dent Today*. 2006;25:70–75.
- Serino G, Strom C. Peri-implantitis in partially edentulous patients: association with inadequate plaque control. *Clin Oral Implants Res*. 2009;20:169–174.
- Mok J, Emami E, Kobayashi T, Feine JS. An oral hygiene brochure for your implant overdenture patients. *J Can Dent Assoc*. 2007;73:713.
- Krennmair G, Suto D, Seemann R, Piehslinger E. Removable four implant-supported mandibular overdentures rigidly retained with telescopic crowns or milled bars: a 3-year prospective study. *Clin Oral Implants Res*. 2012;23:481–488.
- Cordaro L, di Torresanto VM, Petricevic N, Jornet PR, Torsello F. Single unit attachments improve peri-implant soft tissue conditions in mandibular overdentures supported by four implants. *Clin Oral Implants Res*. 2013;24:536–542.
- Keshk AM, Alqutaibi AY, Algabri RS, Swedan MS, Kaddah A. Prosthodontic maintenance and peri-implant tissue conditions for telescopic attachment-retained mandibular implant overdenture: systematic review and meta-analysis of randomized clinical trials. *Eur J Dent*. 2017; 11:559–568.