

# Autotransplantation of third molars with completely formed roots into surgically created sockets and fresh extraction sockets: a 10-year comparative study

H. J. Yu, P. Jia, Z. Lv, L. X. Qiu  
Peking University School and Hospital of  
Stomatology, Haidian District, Beijing, China

H. J. Yu, P. Jia, Z. Lv, L. X. Qiu: *Autotransplantation of third molars with completely formed roots into surgically created sockets and fresh extraction sockets: a 10-year comparative study.* *Int. J. Oral Maxillofac. Surg.* 2017; 46: 531–538. © 2016 International Association of Oral and Maxillofacial Surgeons. Published by Elsevier Ltd. All rights reserved.

**Abstract.** The aim of this study was to analyze and compare the long-term clinical outcomes of mature third molar autotransplantation in surgically created sockets and fresh extraction sockets with regard to survival and functional success rates. A total of 65 third molars with completely formed roots were autotransplanted in 60 patients (average age 33.1 years). Thirty-six of the teeth were autotransplanted into surgically created sockets with or without guided bone regeneration (GBR; delayed autotransplantation), while 29 were autotransplanted into fresh extraction sockets (immediate autotransplantation; control group). All patients underwent annual clinical and radiographic examinations (average follow-up 9.9 years, range 7–13 years). The survival rates for the control, GBR, and no GBR groups were 93.1%, 95.2%, and 80.0%, respectively, with no significant differences among the groups. There were no statistically significant differences among the groups with regard to the frequency of inflammatory root resorption or root ankylosis. Age did not influence the clinical outcomes. These results suggest that the autotransplantation of third molars with completely formed roots is effective in both surgically created and fresh extraction sockets and provides a high long-term success rate if cases are selected and treated appropriately.

**Key words:** tooth autotransplantation; complete root formation; guided bone regeneration; third molars; extraction socket.

Accepted for publication 15 December 2016  
Available online 3 January 2017

The autotransplantation of third molars has become a useful and acceptable treatment option for missing posterior teeth in the human dentition.<sup>1</sup> Successful tooth transplantation provides improved aesthetics, arch forms and dentofacial development, mastication, speech, and arch integrity. The total cost of transplantation is also much lower than that of implant treatment.<sup>2</sup>

The autotransplantation of immature third molars has been performed for several years.<sup>3</sup> However, only a few studies have reported the clinical outcomes of autotransplantation of third molars with completely formed roots.<sup>3,4</sup> Although it has been reported that survival rates of >95% can be obtained after implant placement, implants cannot be used in all cases. The autotransplantation of teeth with complete root formation is indicated for the replacement of one or more lost teeth as a cost-effective treatment alternative to implants.

Revascularization of the pulp is not expected after the transplantation of mature teeth.<sup>1</sup> The histological analysis conducted by Kristerson and Andreasen revealed that root resorption becomes more prominent as root development progresses.<sup>5</sup> Mejare et al. reported a cumulative survival rate of 81.4% over a 4-year follow-up,<sup>3</sup> while other studies have reported survival rates ranging from 71% to 95% after 1 to 3 years of follow-up.<sup>1,4</sup> However, it appears that no study has assessed the outcomes of the autotransplantation of mature third molars over a long-term follow-up period.

One of the basic prerequisites for successful autotransplantation is an appropriate recipient site.<sup>6</sup> Recipient site conditions vary according to the timing of tooth loss, and different surgical techniques are used under different conditions. For patients requiring the replacement of teeth that cannot be retained, autotransplantation can be performed immediately after extraction of the tooth in question. In such cases, the recipient site generally has adequate bone and can easily be prepared to allow for good approximation between the transplanted tooth and bone.<sup>7</sup>

For patients with conditions such as congenitally missing teeth or early tooth loss, the recipient site for autotransplantation needs to be created surgically. In such cases, there is marked horizontal bone loss at the recipient site, which provides inadequate support for the transplanted tooth.<sup>8</sup> When donor teeth are placed into recipient sites with an inadequate buccolingual space, protrusion of the roots through a bone dehiscence and resorption of the alveolar ridge may occur.<sup>9</sup>

In a study by Aoyama, a narrow recipient site was observed in all failed cases of mature tooth autotransplantation.<sup>4</sup> Thus, a lack of buccal bone plate and a narrow recipient site are considered risk factors for treatment failure.<sup>4</sup> A splitting osteotomy of the alveolar process has been recommended for such cases.<sup>8</sup> However, the splitting osteotomy technique negatively influences the treatment outcome because of inadequate recipient sites and difficult closure.<sup>10</sup> As an alternative, graft materials can be placed over the exposed root to create space for bone regeneration.<sup>11</sup> For the treatment of bony defects around implants, Simion et al. used polylactic acid/polyglycolic acid membranes stabilized with fixation screws or nails and autogenous bone chips to create space.<sup>12</sup> Bone substitutes and guided bone regeneration (GBR) have also been used extensively for the management of bone volume deficiency. However, very few clinical studies have investigated the application of GBR to facilitate mature third molar autotransplantation in patients with osseous defects at the recipient site.<sup>13</sup>

The aim of this study was to analyze and compare the long-term clinical outcomes of mature third molar autotransplantation in surgically created sockets (with or without GBR) and fresh extraction sockets with regards to survival and functional success rates. The indications for the treatment options and surgical techniques were investigated over a long-term follow-up period.

## Materials and methods

This was a prospective study. The study protocol was evaluated and approved by the institutional ethics committee of Peking University School of Stomatology prior to patient selection. All patients who were able to understand the procedure and sign an informed consent form were eligible for inclusion in this trial.

## Clinical records

Patients were recruited from those referred to the study institution between 2003 and 2006. All patients with one or two non-retainable teeth, early tooth loss, or a congenitally missing tooth in the premolar or molar region were considered eligible. Patients were recruited according to the inclusion and exclusion criteria detailed in Table 1.

## Treatment plan

All surgical procedures were performed by a single surgeon using standardized

Table 1. Inclusion and exclusion criteria for participation in the study.

Inclusion criteria	
Voluntary informed consent	
Age >18 years	
1–2 non-retainable teeth, early tooth loss, or a congenitally missing tooth in the premolar or molar region	
Third molars with completely formed roots and with a suitable shape and dimension for the recipient site after clinical and radiographic evaluation	
Edentulous opposing dentition with a denture (implant-borne or conventional) or natural teeth	
Rejection of implant placement	
Exclusion criteria	
General contraindications for transplant surgery	
Severe haemophilia	
History of irradiation in the head and neck region less than 1 year before the study	
Poor oral hygiene	
Uncontrolled diabetes	
Pregnant or lactating	
Psychiatric problems or unrealistic expectations	
HIV infection	
Severe bruxism or clenching habits	
Presence of osseous lesions	

surgical techniques. Patients were categorized into three groups. Patients admitted for eventual autotransplantation after the extraction of a molar tooth served as controls. In the other two test groups, patients received third molar autotransplantation in surgically created sockets either with or without GBR.

## Removal of donor teeth

In the control group, the donor teeth were extracted under local anaesthesia (lidocaine 2% with epinephrine 1:100,000). Following incision placement and full-thickness flap reflection for complete exposure of the surgical site, an osteotomy was performed for minimally traumatic removal of the donor tooth. Care was taken to preserve the periodontal ligament attached to the root as much as possible. After the diameter and length of the root(s) had been measured, the donor tooth was placed back into the extraction socket for preservation. The maximum allowable extraoral time before transplantation was 30 min.

## Surgical treatment of the recipient site

For patients with non-retainable teeth, autotransplantation was performed immediately after extraction of the tooth in question (control group). Following extraction and removal of the intra-alveolar

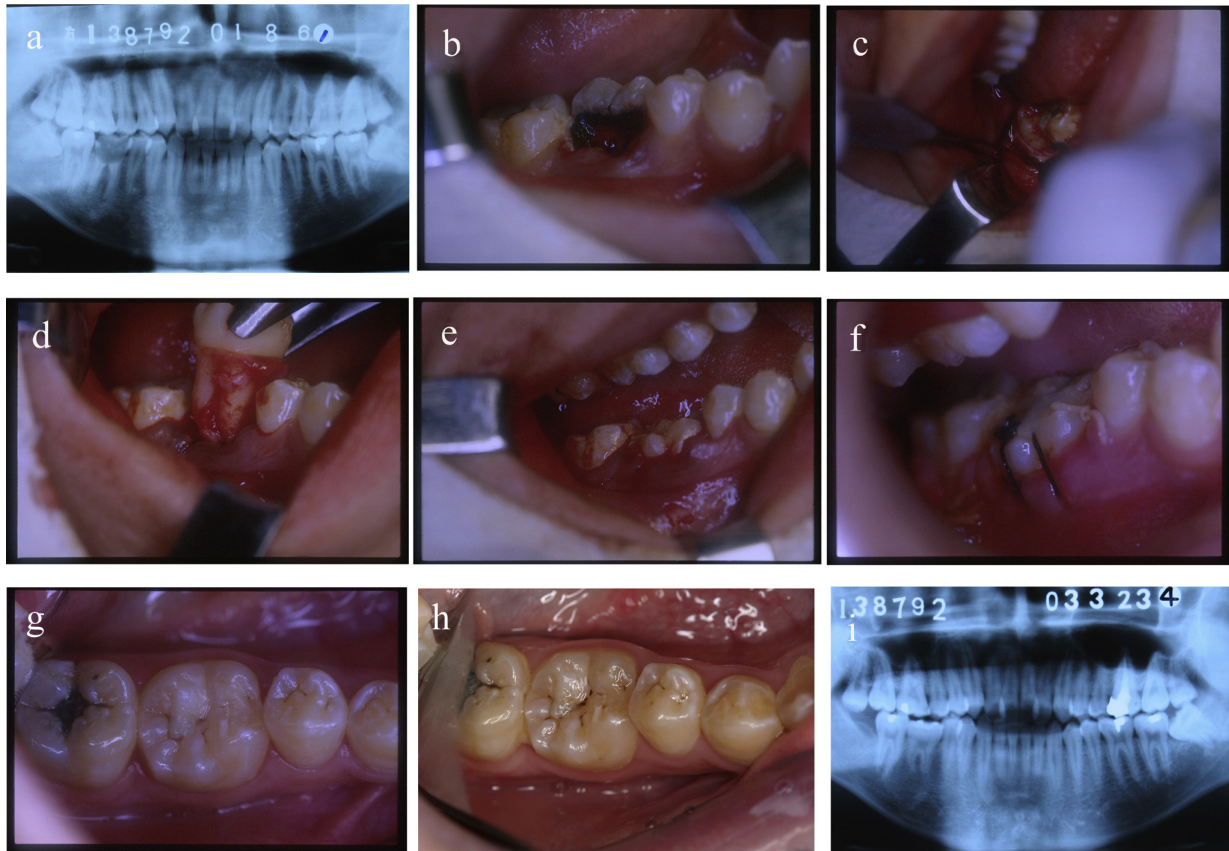


Fig. 1. Autotransplantation of a mature third molar tooth in a fresh extraction socket: (a) initial panoramic radiograph; (b) carious lesion in the mandibular right first molar (recipient site); (c) view of the mandibular right third molar in the alveolus (donor site); (d) transplantation of the donor tooth in the prepared receptor alveolus; (e) placement of the donor tooth in the recipient area; (f) suturing and fixation of the transplanted tooth; (g) postoperative view at 2 weeks after surgery; (h) postoperative view at 3 months after surgery; (i) final radiograph obtained 3 months after surgery.

septa using burs, the recipient site was adjusted using dental implant drills (Thommen Medical AG, Grenchen, Switzerland). No additional surgical procedures were required (Fig. 1).

For patients with early tooth loss or congenitally missing teeth (test group 1), the recipient bed was made slightly larger than the donor site and was created surgically using dental implant drills of an increasing diameter; this was performed under abundant sterile saline irrigation to avoid thermal damage to the bone (Fig. 2). For patients with marked horizontal alveolar bone loss or partial loss of the buccal bone wall at the recipient site (test group 2), GBR was performed after transplantation. Bio-Oss and Bio-Oss Collagen (Geistlich Pharma AB, Wolhusen, Switzerland) and a few autogenous bone chips collected during the osteotomy were used to fill the buccal bone defects, after which a resorbable membrane was placed for coverage (Bio-Gide; Geistlich Pharma).

The donor tooth was placed into the recipient bed as soon as possible; the aver-

age duration between removal and transplantation of the donor tooth was 15 min.

#### Fixation of the autotransplanted tooth

The transplanted donor teeth were stabilized with non-absorbable surgical sutures, which were removed 2–3 weeks after surgery to avoid ankylosis.

The dental surgeon ensured that a 40- $\mu$ m-thick articulating paper could pass between the teeth without resistance, thus maintaining the transplanted teeth out of occlusion. The configuration of the transplanted teeth was adjusted in accordance with the contralateral teeth.

#### Postoperative care

After surgery, all patients were prescribed antibiotics for 1 week and were instructed to rinse with 0.2% chlorhexidine for 20 s three times a day for 3 weeks. Healing was evaluated after 2 weeks. Patients older than 20 years underwent endodontic treatment. For patients under the age of 20 years, vitality

tests were performed with an electrometric pulp tester. At the 3–6-month recall, transplanted teeth were treated endodontically with calcium hydroxide if the teeth reacted negatively to sensitivity tests. During the postoperative observation period, root canal treatment was initiated promptly if any sign of pulp infection was observed.

#### Follow-up

The average duration of follow-up was 9.9 years (range 7–13 years). The patients were evaluated clinically and radiographically at 1, 3, and 12 months after surgery and annually thereafter.

#### Clinical examinations

A single clinician, who was not involved in the treatment of the patients, performed all of the clinical examinations without knowledge of the group allocations. The success of autotransplanted teeth was assessed mainly based on peri-apical healing and periodontal health. These factors included an absence of pathological mo-

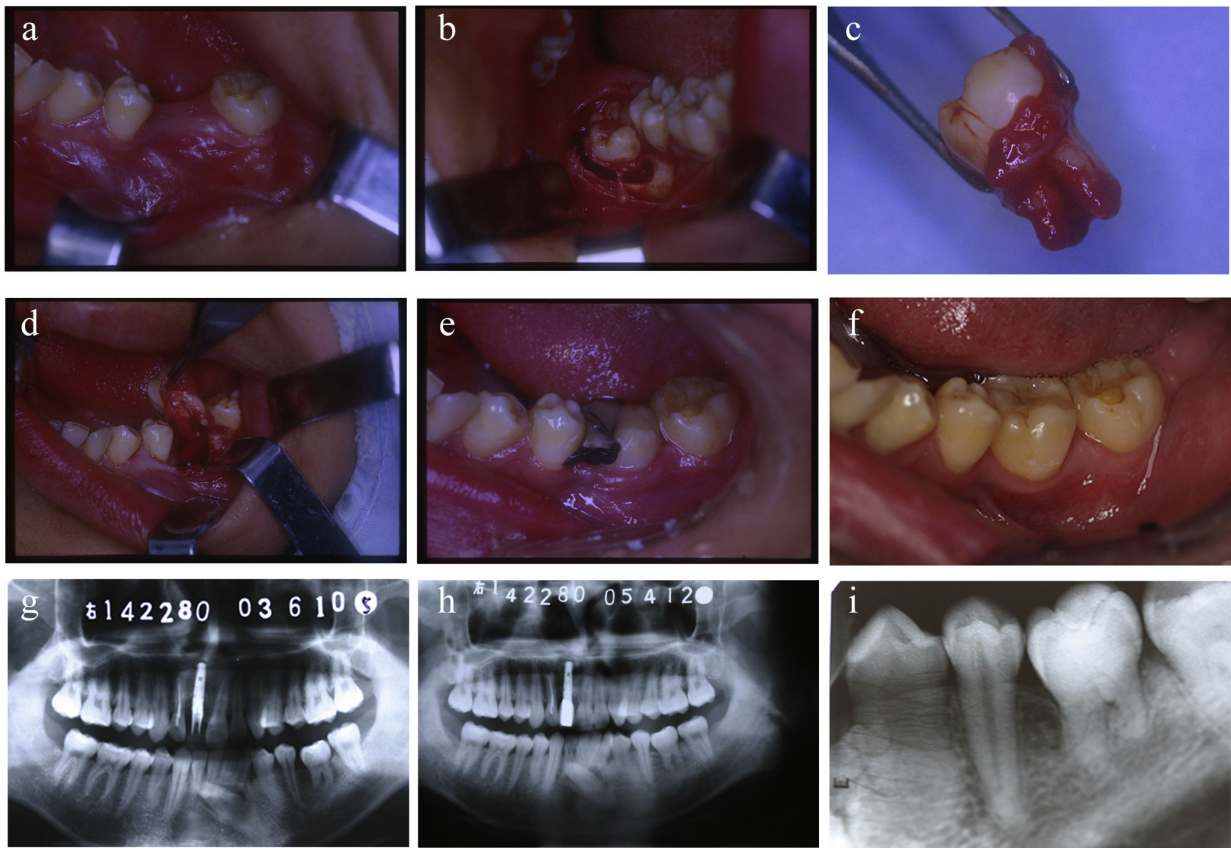


Fig. 2. Autotransplantation of a mature third molar tooth in a surgically created socket: (a) missing mandibular left first molar (recipient site); (b) minimally traumatic extraction of the mandibular right third molar (donor site); (c) remaining collar of the follicular sac after donor tooth extraction; (d) transplantation of the donor tooth in the prepared receptor alveolus; (e) suturing and fixation of the transplanted tooth; (f) postoperative view at 3 months after surgery; (g) panoramic radiograph obtained immediately after surgery; note an ectopically unerupted mandibular canine, which was left untreated; (h) panoramic radiograph obtained 3 months after surgery; (i) peri-apical radiograph obtained 6 months after surgery.

bility and absence of a continuous radiolucency around the transplant. Other parameters for assessing the success of transplants included ankylosis, inflammatory root resorption, and inflammation at the recipient site.

**Radiographic examinations**

Panoramic radiographs were obtained before and after autotransplantation and peri-apical radiographs were obtained after autotransplantation for the assessment of root resorption, the periodontal condition, the lamina dura, and ankylosis.

**Statistical analysis**

The survival time was censored when there was a follow-up period but failure of the transplant had not occurred. A multivariate Cox regression model was used to analyze the influence of various factors on the survival rate. IBM SPSS

Statistics version 20.0 software (IBM Corp., Armonk, NY, USA) was used for all statistical analyses. Significant differences in clinical and radiographic findings among the groups were determined using the  $\chi^2$  test or Fisher's exact test, as appropriate. A *P*-value of <0.05 was considered statistically significant.

**Results**

Follow-up was terminated at 31 August 2015 in this study. The study initially included a total of 72 patients recruited consecutively between 2003 and 2006 for the autotransplantation of third molars with completely formed roots after clinical and radiographic evaluations. Five patients with uneventful healing after surgery moved away to other cities during the first year after surgery and were therefore withdrawn from further check-ups. Seven patients could not be contacted by phone, as they lived in remote locations or had

work-related conflicts. The remaining 60 patients were included in this trial.

The survival time was defined as the number of years from transplantation to the time of censoring or to the date on which the transplant was recorded as unsuccessful. Overall, 65 third molars with completely formed roots were autotransplanted in the 60 patients (32 female and 28 male; average age at the time of transplantation 33.1 years, range 19–55 years). Table 2 shows the number and distribution of transplanted teeth in the three groups according to sex, age at transplantation, and the observation time. Tables 3 and 4 show the distribution of the transplanted teeth and recipient sites in the maxilla and mandible.

In total, 29 mature third molars were transplanted into fresh extraction sockets (control group) and 36 into surgically created sockets (delayed transplantation). The survival rates in the two groups were 93.1% and 88.9%, respectively, with no

Table 2. Number and distribution of transplanted teeth by sex, age at transplantation, and duration of observation.

	Recipient site			Total
	Prepared socket		Fresh socket	
	Bone graft	No bone graft		
Number of transplanted teeth	21	15	29	65
Sex <sup>a</sup>				
Male	6 (7)	8 (8)	14 (14)	28 (29)
Female	11 (14)	7 (7)	14 (15)	32 (36)
Average age, years (range)	27.7 (20–34)	36.8 (21–49)	33.1 (19–55)	33.1 (19–55)
Average observation time, years (range)	9.8 (8–12)	10.1 (8–11)	9.7 (7–13)	9.9 (7–13)

<sup>a</sup>Data presented as the number of patients (number of teeth).

Table 3. Distribution of transplanted teeth in the maxillary recipient sites ( $n = 21$ ).

Donor teeth	Recipient site			
	Premolar		Molar	
	Prepared sockets	Fresh sockets	Prepared sockets	Fresh sockets
Maxilla	2	0	9	2
Mandible	3	0	3	2
Total	5 (7.7%)	0	12 (18.5%)	4 (6.2%)

significant difference between groups ( $P > 0.05$ ). In the delayed transplantation group, the survival rates for the GBR and no GBR subgroups were 95% and 80%, respectively, with no significant difference between the groups ( $P > 0.05$ ). Furthermore, there were no significant differences among the GBR (14.3%;  $n = 3$ ), no GBR (6.7%;  $n = 1$ ), and control (10.3%;  $n = 3$ ) groups with regard to the frequency of inflammatory root resorption (Table 5). There were also no significant differences between the three groups in the incidence of ankylosis (9.5%, 6.7%, and 10.3% for the GBR, no GBR, and control group, respectively).

Multivariate Cox regression analysis revealed age to be an independent factor affecting the prognosis of autotransplanted teeth; the hazard of transplanted tooth loss increased with age (hazard ratio = 1.14,  $P = 0.04$ ). Autotransplantation in surgically created (with or without GBR) or fresh extraction sockets and sex were not significant factors (Table 6).

### Discussion

In the present study, the long-term clinical outcomes of mature third molar autotransplantation in surgically created sockets with or without GBR and fresh extraction sockets were analyzed and compared, and

no significant differences in outcomes were found.

A high success rate has been reported for the autotransplantation of immature third molars.<sup>2</sup> When the donor tooth has incompletely formed roots, the probability of pulp healing increases.<sup>4</sup> In another study, comparable results were obtained when immature third molars were autotransplanted in fresh extraction sockets and surgically created sockets in edentulous regions.<sup>2</sup>

The present study supports the hypothesis that mature third molar autotransplantation for the replacement of a missing or non-retainable posterior tooth is a reasonable

Table 4. Distribution of transplanted teeth in the mandibular recipient sites ( $n = 44$ ).

Donor teeth	Recipient site			
	Premolar		Molar	
	Prepared sockets	Fresh sockets	Prepared sockets	Fresh sockets
Maxilla	4	0	5	4
Mandible	1	2	9	19
Total	5 (7.7%)	2 (3.1%)	14 (21.5%)	23 (35.4%)

Table 5. Complications of transplanted teeth during follow-up.

	Recipient site			Total
	Prepared socket		Fresh socket	
	Bone graft	No bone graft		
Transplanted teeth, $n$	21	15	29	65
Inflammatory root resorption, $n$ (%)	3 (14.3%)	1 (6.7%)	3 (10.3%)	7 (10.8%)
Ankylosis, $n$ (%)	2 (9.5%)	1 (6.7%)	3 (10.3%)	6 (9.2%)
Lost transplant, $n$ (%)	1	3	2	6
Survival rate	95.2%	80.0%	93.1%	90.8%

Table 6. Results of multivariate Cox regression analysis.

Variable	B	SE	P-value	Exp(B)
Group <sup>a</sup>			0.66	
Group 1a (surgically created sockets)	1.24	1.45	0.39	3.46
Group 1b (fresh extraction sockets)	0.62	0.95	0.51	1.86
Sex	-1.31	1.11	0.24	0.27
Age	0.13	0.06	0.04	1.14

SE, standard error.

alternative to implant treatment, even though the pulp of a mature tooth cannot regenerate and the tooth will require post-operative endodontic treatment. The overall long-term survival rate obtained in the present study (90.80%) is comparable with those reported previously.<sup>14,15</sup> Minimally traumatic surgical extraction is the key to successful autotransplantation. Specifically, during the process of extraction and extraoral storage, great care should be taken to protect Hertwig's epithelial root sheath and the pulp vitality.<sup>16</sup> In the present study, it was found that the risk of autotransplanted tooth loss increased with age, similar to the findings of previous studies.<sup>17,18</sup> Age-related changes in the mineral density of bone may increase the risk of bacterial infection and impair revascularization.<sup>15</sup>

Different surgical techniques are used for autotransplantation depending on the timing of tooth loss. Conventionally, the third molar is placed into the freshly created extraction socket immediately after extraction of a non-retainable tooth.<sup>7</sup> However, in patients with congenitally missing teeth or early tooth loss, the recipient site has to be created surgically.<sup>19</sup> Although the latter technique has been associated with several difficulties, as discussed below, no significant differences in outcomes were found in the present study.

The trauma caused by preparation of a new socket induces delayed revascularization and increases the risk of thermal damage to the bone.<sup>20</sup> Furthermore, compared with immature third molars, transplants with completely formed roots require a greater depth at the recipient site, which requires more time for preparation and careful checking to avoid encroachment on important anatomical structures, such as the mandibular canal, due to alveolar bone atrophy.<sup>20</sup> In fresh extraction sockets, a sufficient depth is generally obtained after simple adjustments. In the present study, internally cooled drills with a high-torque and low-speed hand-piece were used for recipient bed preparation with minimal thermal damage, and recipient bone contouring was used for compatibility with the donor tooth.<sup>21</sup> Cervical approximation between

the root surface of the transplanted tooth and bone is a key factor in bone formation, because the bone tissue below the cervical portion is a closed wound with decreased chances of infection and an increased tendency for adequate healing without complications.<sup>22</sup>

After tooth extraction, the buccal and lingual walls of the alveolus undergo substantial resorption.<sup>23</sup> If the buccopalatal or buccolingual width of the recipient site is inadequate to accommodate the donor tooth, excess bone may be removed and the roots of the donor tooth can protrude through a bone dehiscence.<sup>3</sup> An inadequate buccolingual width can result in alveolar ridge resorption, and a lack of buccal bone plate has been reported to contribute to treatment failure.<sup>24</sup> In another study, a narrow recipient site was observed in all cases of unsuccessful mature tooth autotransplantation.<sup>4</sup> The use of free bone autografts is advocated for cases of alveolar process atrophy.<sup>25</sup> Although some authors have argued that the use of free bone autografts with autotransplantation of immature third molars may negatively influence the treatment outcome because of an impaired blood supply through diffusion,<sup>3</sup> no significant association between the use of GBR and long-term survival of the autotransplanted teeth was found in the present study.

GBR has been used successfully for the management of peri-implant bone defects and to augment the height and width of atrophic alveolar ridges prior to implant placement, with the use of bone substitutes for space creation.<sup>26</sup> Bovine bone mineral has been described as an osteoconductive graft that can fill bone defects and result in periodontal regeneration with new cementum, new ligamentous tissue, and new alveolar bone around previously diseased root surfaces.<sup>27</sup> The new tissue has been demonstrated to compensate for the hard tissue loss to a great extent.<sup>28</sup> In the present study, no significant differences in outcomes were observed between the GBR group and the control group. These results are in agreement with those of a previous study performed by the present authors.<sup>13</sup> Thus, GBR can be useful for

autotransplantation at recipient sites with bone defects.

In the fresh extraction socket, sufficient space and depth for transplant placement are generally obtained following the removal of intra-alveolar septae. Bone graft materials were applied unnecessarily in the space between the bone walls and transplant roots in the present study, which has also been done in other studies.<sup>20</sup> The distance between the donor root surface and the recipient site tissue plays a decisive role in providing sufficient nutrition to the transplant.<sup>20</sup> Therefore, if a fresh extraction socket is too large for the donor tooth, GBR is a good alternative to fill the gap.

The use of GBR in surgically created sockets complicates the surgical technique. Additional surgical procedures are reported to have a negative effect on the pulpal and periodontal conditions after autotransplantation of immature third molars.<sup>7</sup> However, no significant differences in the success rate were observed among the GBR, no GBR, and control groups in the present study.

The extraoral storage time influences the prognosis of tooth autotransplantation.<sup>4</sup> In the present study, the extra-alveolar time was less than 30 min (average 15 min), and such procedures require skilled operators. It is considered that the pulp of completely mature teeth cannot survive after autotransplantation. Kristerson and Andreasen reported that pulp revascularization was observed in 100% of teeth with initial root development but decreased to 0% for teeth with fully developed roots.<sup>5</sup> The American Association of Endodontists has recommended that the pulp of teeth with close apices be extirpated 7 to 14 days after transplantation; otherwise the necrotic pulp and subsequent infection may result in inflammatory resorption and decrease the survival time.<sup>29</sup> Endodontic treatment can also be completed before transplantation. However, this approach is not advisable as it could prolong the extraoral storage time and increase the risk of root resorption. Andreasen also examined the root development and pulpal healing subsequent to autotransplantation.<sup>16</sup> Transplanted teeth with incomplete root formation have a 96% rate of pulpal healing, compared to 15% for transplanted teeth even with complete root formation. In the present study, the pulp vitality in patients under 20 years of age was monitored after the initial 6 weeks. Endodontic treatment was performed if the transplanted tooth was found to react negatively to electrometric pulp testing. The final endodontic treatment

was performed at around a year postoperatively.

In the present study, multivariate Cox regression analysis revealed age to be an independent factor affecting the prognosis of the autotransplanted teeth. This is in accordance with other studies. Age decreases the regeneration ability of transplanted tissue after surgery and is associated with an increased risk of bacterial infection of the donor tooth owing to the increasing rate of dental caries and periodontal inflammation of the donor tooth. Furthermore, the difficulty of extraction and preparation of the recipient area increases with age, due to the increased mineralization density of bone.

The rates of complications following autogenous tooth transplantation, which include root resorption and attachment loss, are lower than for implants. The results of the present study indicate that the autotransplantation of mature third molar teeth is a reasonable treatment alternative to implant treatment in partially edentulous adult patients, especially when performed immediately following or soon after the removal of the damaged tooth.

The present investigation was limited by the small sample size. In addition, changes in bone height and width were not analyzed through three-dimensional projection, which is a more accurate and reliable approach.

In conclusion, the results of the present study suggest that mature third molar autotransplantation in both fresh extraction sockets and surgically created sockets is associated with good long-term outcomes. Even in patients with extensive buccolingual alveolar bone atrophy, promising and optimal functional outcomes can be obtained with the use of GBR. Modified surgical techniques to ensure the minimally traumatic removal of donor teeth can also increase the success rate of mature third molar autotransplantation.

#### Funding

None.

#### Competing interests

None declared.

#### Ethical approval

The study protocol was evaluated and approved by the Institutional Ethics Committee of the Peking University School of Stomatology (Ref. PKUSSIRB-201310081).

#### Patient consent

All patients provided written informed consent.

#### References

- Sugai T, Yoshizawa M, Kobayashi T, Ono K, Takagi R, Kitamura N, et al. Clinical study on prognostic factors for autotransplantation of teeth with complete root formation. *Int J Oral Maxillofac Surg* 2010;**39**:1193–203.
- Bauss O, Engelke W, Fenske C, Schilke R, Schweska-Polly R. Autotransplantation of immature third molars into edentulous and atrophied jaw sections. *Int J Oral Maxillofac Surg* 2004;**33**:558–63.
- Mejare B, Wannfors K, Jansson L. A prospective study on transplantation of third molars with complete root formation. *Oral Surg Oral Med Oral Pathol Endod* 2004;**97**:231–8.
- Aoyama S, Yoshizawa M, Niimi K, Sugai T, Kitamura N, Saito C. Prognostic factors for autotransplantation of teeth with complete root formation. *Oral Surg Oral Med Oral Pathol Oral Radiol* 2012;**114**:S216–28.
- Kristerson L, Andreasen JO. Influence of root development on periodontal and pulpal healing after replantation of incisors in monkeys. *Int J Oral Surg* 1984;**13**:313–23.
- Shahbazian M, Jacobs R, Wyatt J, Denys D, Lambrichts I, Vinckier F, et al. Validation of the cone beam computed tomography-based stereolithographic surgical guide aiding autotransplantation of teeth: clinical case-control study. *Oral Surg Oral Med Oral Pathol Oral Radiol* 2013;**115**:667–75.
- Bauss O, Zonios I, Engelke W. Effect of additional surgical procedures on root development of transplanted immature third molars. *Int J Oral Maxillofac Surg* 2008;**37**:730–5.
- Akiyama Y, Fukuda H, Hashimoto K. A clinical and radiographic study of 25 autotransplanted third molars. *J Oral Rehabil* 1998;**25**:640–4.
- Cross D, El-Angbawi A, McLaughlin P, Keightley A, Brocklebank L, Whitters J, et al. Developments in autotransplantation of teeth. *Surgeon* 2013;**11**:49–55.
- Pogrel MA. Evaluation of over 400 autogenous tooth transplants. *J Oral Maxillofac Surg* 1987;**45**:205–11.
- Imazato S, Fukunishi K. Potential efficacy of GTR and autogenous bone graft for autotransplantation to recipient sites with osseous defects: evaluation by re-entry procedure. *Dent Traumatol* 2004;**20**:42–7.
- Simion M, Misitano U, Gionso L, Salvato A. Treatment of dehiscences and fenestrations around dental implants using resorbable and nonresorbable membranes associated with bone autografts: a comparative clinical study. *Int J Oral Maxillofac Implants* 1997;**12**:159–67.
- Yu HJ, Qiu LX, Wang XZ. Long-term follow-up of autogenous canine transplants with application of guided bone regeneration. *Int J Oral Maxillofac Surg* 2014;**43**:355–61.
- Tsurumachi T, Kakehashi Y. Autotransplantation of a maxillary third molar to replace a maxillary premolar with vertical root fracture. *Int Endod J* 2007;**40**:970–8.
- Yoshino K, Kariya N, Namura D, Noji I, Mitsuhashi K, Kimura H, et al. Risk factors affecting third molar autotransplantation in males: a retrospective survey in dental clinics. *J Oral Rehabil* 2012;**39**:821–9.
- Andreasen JO. Effect of extra-alveolar period and storage media upon periodontal and pulpal healing after replantation of mature permanent incisors in monkeys. *Int J Oral Surg* 1981;**10**:43–53.
- Kingsmill VJ. Post-extraction remodeling of the adult mandible. *Crit Rev Oral Biol Med* 1999;**10**:384–404.
- Schwartz O, Bergmann P, Klausen B. Autotransplantation of human teeth. A life-table analysis of prognostic factors. *Int J Oral Surg* 1985;**14**:245–58.
- Nethander G, Skoglund A, Kahnberg KE. Experimental autogenous tooth transplantation in the dog: a comparison between one- and two-stage surgical techniques. *Acta Odontol Scand* 2003;**61**:223–9.
- Bauss O, Zonios I, Rahman A. Root development of immature third molars transplanted to surgically created sockets. *J Oral Maxillofac Surg* 2008;**66**:1200–11.
- Benington IC, Biagioni PA, Briggs J, Sheridan S, Lamey PJ. Thermal changes observed at implant sites during internal and external irrigation. *Clin Oral Implants Res* 2002;**13**:293–7.
- Bae JH, Choi YH, Cho BH, Kim YK, Kim SG. Autotransplantation of teeth with complete root formation: a case series. *J Endod* 2010;**36**:1422–6.
- Rothamel D, Schwarz F, Herten M, Chiriac G, Pakravan N, Sager M, et al. [Dimensional ridge alterations following tooth extraction. An experimental study in the dog]. *Mund Kiefer Gesichtschir* 2007;**11**:89–97.
- Ko JM, Paik CH, Choi S, Baek SH. A patient with protrusion and multiple missing teeth treated with autotransplantation and space closure. *Angle Orthod* 2014;**84**:561–7.
- Frenken JW, Baart JA, Jovanovic A. Autotransplantation of premolars. A retrospective study. *Int J Oral Maxillofac Surg* 1998;**27**:181–5.
- Chiapasco M, Casentini P, Zaniboni M, Corsi E. Evaluation of peri-implant bone resorption around Straumann Bone Level implants placed in areas reconstructed with autogenous vertical onlay bone grafts. *Clin Oral Implants Res* 2012;**23**:1012–21.
- Iezzi G, Scarano A, Mangano C, Cirotti B, Piattelli A. Histologic results from a human implant retrieved due to fracture 5 years after insertion in a sinus augmented with anor-

- ganic bovine bone. *J Periodontol* 2008;**79**:192–8.
28. Araujo MG, Linder E, Lindhe J. Bio-Oss collagen in the buccal gap at immediate implants: a 6-month study in the dog. *Clin Oral Implants Res* 2011;**22**:1–8.
29. Cohen AS, Shen TC, Pogrel MA. Transplanting teeth successfully: autografts and

allografts that work. *J Am Dent Assoc* 1995;**126**:481–5. quiz 500.

Address:  
*Lixin Qiu*  
4th Clinical Division  
Peking University Hospital of Stomatology  
F1  
A Tower

*Jia Tai International Mansion*  
No. 41  
Dongsihuanzhong Road  
Chaoyang District  
Beijing  
PR China  
Tel: +86 10 85715955; Fax: +86 10 85715935  
E-mail: [qiu\\_lixin@yahoo.net](mailto:qiu_lixin@yahoo.net)