

# Lower Second Molar Extraction in Correction of Severe Skeletal Class III Malocclusion

Jiuxiang Lin<sup>a</sup>; Yan Gu<sup>b</sup>

## ABSTRACT

The purpose of this study was to evaluate dentoskeletal and soft-tissue profile changes after extraction of lower second molars and treatment using the Tip-Edge technique in severe Class III subjects. Thirteen patients with severe skeletal Class III malocclusion (four males, nine females), diagnosed as requiring orthognathic surgery, but who rejected surgical therapy, were included in the study. The average age was  $13.2 \pm 0.8$  years. Lateral cephalometric films taken at the beginning and the end of treatment were analyzed using the Pancherz analysis and a traditional cephalometric analysis. The arithmetic mean and standard deviation were calculated for each variable. Paired *t*-test was performed to evaluate significant treatment change. After active treatment, dramatic overjet change was noted, with an average value of 5.5 mm ( $P < .001$ ). Inclination of lower incisors was decreased  $12.0^\circ$  when measured to the mandibular plane ( $P < .001$ ). Inclination of upper incisors was increased by  $2.1^\circ$  to the SN plane ( $P > .05$ ). A negative value of the distance between upper and lower lip position to Sn-Pg' at the beginning of treatment changed to a positive value ( $P < .001$ ). The results of this preliminary study suggest that success in the treatment of some severe Class III deformity in the permanent dentition can be achieved with fixed appliances and extraction of lower second molars. A remarkable soft-tissue change was noted after the treatment, and concave facial profiles changed to straight profiles. (*Angle Orthod* 2006;76:217–225.)

**KEY WORDS:** Skeletal Class III malocclusion; Lower second molars

## INTRODUCTION

The decision to treat the severe skeletal Class III malocclusion by surgical means or nonsurgical orthodontic approaches still lacks a clear consensus. A facial profile is always one of the main concerns of patients to seek treatment for skeletal Class III deformities, and orthognathic surgery has been demonstrated to modify the skeletal pattern in addition to producing dramatic facial profile changes.<sup>1,2</sup> However, the majority of patients in China do not readily accept surgery because of potential surgical complications and seek an orthodontic solution. In general, a fixed appliance

in combination with extractions is considered the only option for nonsurgical management of skeletal deformities in the permanent dentition.

The MEAW (multiloop edgewise archwire) technique is sometimes used for correction of severe Class III malocclusion.<sup>3–5</sup> The extraction index used in the MEAW technique depends on the overbite depth indicator, the anteroposterior dysplasia indicator, esthetic line, interincisal angle, and lip position. The lower third molars were often extracted with the MEAW technique in Class III subjects.

Tip-Edge is among the fixed appliances currently used. This appliance characteristically uses a continuous light force of about 50–60 g to achieve tipping movement of teeth and then to upright and move the teeth to an acceptable position.<sup>6–13</sup>

The purpose of this study is to evaluate dentoskeletal change and soft-tissue profile change after extraction of lower second molars and treatment with Tip-Edge in severe Class III subjects.

## MATERIALS AND METHODS

Thirteen patients (four male, nine female; mean age  $13.2 \pm 0.8$  years; range 12.0–17.1 years) with severe

<sup>a</sup> Professor, Department of Orthodontics, School of Stomatology, Peking University, Beijing, People's Republic of China.

<sup>b</sup> Associate Professor, Department of Orthodontics, School of Stomatology, Peking University, Beijing, People's Republic of China.

Corresponding author: Jiuxiang Lin, BDS, MDS, PhD, Department of Orthodontics, School of Stomatology, Peking University, No. 22 Zhong Guan Cun Southern Street, Beijing 100081, People's Republic of China (e-mail: jxlin@pku.edu.cn)

Accepted: April 2005. Submitted: February 2005.

© 2006 by The EH Angle Education and Research Foundation, Inc.

skeletal Class III malocclusion in the permanent dentition were included in the study. The selection criteria included (1) full mesial or superior mesial Class III molar relationship, with maxillary first molar occluding in the buccal groove of the mandibular second molars; (2) no mandibular shift; (3)  $ANB < -1.5^\circ$ ; (4) concave facial profile with high mandibular plane angle from clinical evaluation; (5) lower third molars present on panoramics; and (6) originally classified as surgery cases by other orthodontists.

All cases were treated with Dr Jiuxiang Lin. The Tip-Edge straight-wire technique was applied in all 13 cases, and all patients were treated with extraction of the lower second molars. The mean duration of treatment was  $2.6 \pm 0.6$  years.

### Cephalometric analysis

Pretreatment and posttreatment cephalograms were taken with the same cephalostat and traced on an acetate paper. Reference points were marked with a sharp pencil by one observer, under optimal conditions. The midpoint between the right and left traced images was used for the bilateral landmarks. Traditional cephalometric analysis using the Pancherz analysis with the occlusal plane and occlusal plane perpendicular (OLp) as reference grids were performed (Figure 1).<sup>14</sup> The soft-tissue measurements included:

1. UL-SnPg': The distance of the most convex point of upper lip to Sn-Pg' line (line connecting subnose and soft tissue, Pg);
2. LL-SnPg': The distance of the most convex point of lower lip to Sn-Pg' line; and
3. UL-SnPg'-LL-SnPg': distance difference of the most convex points of upper and lower lips to Sn-Pg' line.

### Statistical analysis

Statistical analysis was performed with SPSS 12.0 for Windows (SPSS Inc, Chicago, IL). The arithmetic mean and standard deviation were calculated for each variable. Paired *t*-test was performed to evaluate treatment effects. The level of significance was  $P > .05$  (NS),  $*P < .05$ ,  $**P < .01$ , and  $***P < .001$ .

### Method error

Accuracy of linear parameters was  $0.2 \pm 0.2$  mm and angular parameters was  $0.1^\circ \pm 0.3^\circ$ , which is comparable with that used in previous investigations.<sup>15</sup>

## RESULTS

### Overjet change

Overjet increased dramatically after active treatment, with the mean value of 5.5 mm ( $P < .001$ ; Table 1).

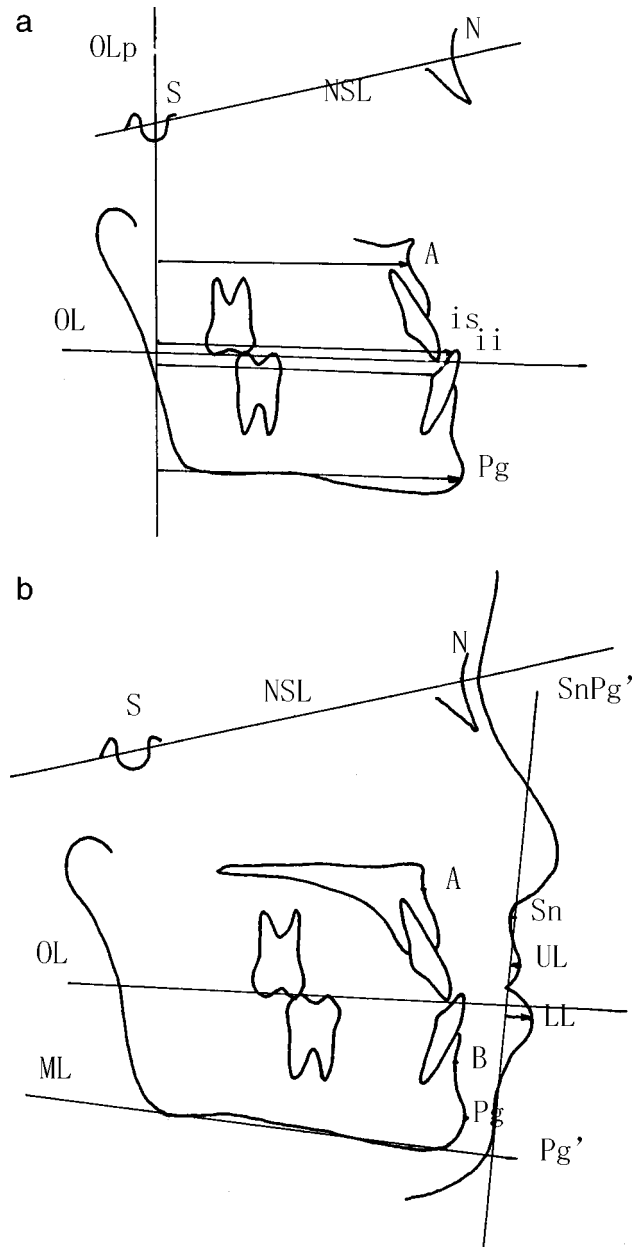


FIGURE 1. (a) Measurements in Pancherz analysis. (b) Reference lines and landmarks used in traditional cephalometric analysis.

### Molar relationship

The molar relationship was improved by a mean of 4.4 mm, which was a significant difference ( $P < .05$ ; Table 1).

### Dental change

The proclination of the upper incisors increased by a mean of  $2.1^\circ$  when measured to the SN plane ( $P > .05$ ; Table 2). A mean retroclination of the lower incisors of  $12.0^\circ$  was found when measured to the mandibular plane ( $P < .001$ ; Table 2). The mean amount

**TABLE 1.** Results of Cephalometric Analysis

	Pretreatment		Posttreatment		PostTx-PreTx		<i>P</i> Value
	Mean	SD	Mean	SD	Mean	SD	
Overjet (is/OLp-ii/Olp)	-2.4	1.6	3.1	1.3	5.5	1.6	***
Molar relationship	-7.5	5.4	-3.1	1.7	4.4	5.0	*
Maxillary base (A/Olp)	74.7	4.9	76.6	6.8	1.9	3.1	*
Mandibular base (Pg/Olp)	92.5	6.5	93.5	8.8	1.0	3.6	NS
Skeletal (A-Pg)	-17.8	5.7	-16.9	5.5	0.9	2.7	NS
Maxillary incisor (is/Olp)	88.1	6.3	90.7	7.5	2.6	3.5	*
Mandibular incisor (ii/Olp)	90.5	6.5	87.6	8.1	-2.8	3.6	*
Maxillary molar (ms/Olp)	56.7	4.2	60.0	6.9	3.1	4.3	*
Mandibular molar (mi/Olp)	65.2	5.4	63.0	7.6	-2.2	3.7	NS
Maxillary incisor (is/Olp-A/Olp)	13.3	2.9	14.1	2.2	0.8	2.2	NS
Mandibular incisor (ii/Olp-Pg/Olp)	-2.1	4.0	-5.9	4.3	-3.8	1.5	***
Maxillary molar (ms/Olp-A/Olp)	-18.0	3.0	-16.8	3.1	1.2	2.2	NS
Mandibular molar (mi/Olp-Pg/Olp)	-26.6	3.8	-30.6	5.5	-4.0	5.9	*
OL-MnPI	20.5	5.6	23.3	7.2	2.9	3.9	*
PP-MnPI	28.6	6.8	30.0	6.4	1.4	2.9	NS
SN-MnPI	36.0	5.7	37.5	6.5	1.5	4.2	NS

NS indicates not significant ( $P > .05$ ).

\*  $P < .05$ .

\*\*  $P < .01$ .

\*\*\*  $P < .001$ .

of lingual movement of the lower incisors was 3.8 mm when measured from the distance of the tip of the lower incisors to the occlusal plane perpendicular ( $P < .001$ ; Table 1). The amount of labial movement of the upper incisors was 0.8 mm when measured from the tip of the upper incisor to the occlusal plane perpendicular ( $P > .05$ ; Table 1).

The upper first molar moved to the mesial a mean of 1.2 mm ( $P > .05$ ; Table 1). Because of the extraction of the lower second molars, the lower first molar moved to the distal a mean of 4.0 mm ( $P < .05$ ; Table 1).

### Skeletal change

The ANB angle increased a statistically significant  $1.3^\circ$  after treatment ( $P < .05$ ; Table 2). "A" point moved forward at the end of the treatment, with an increased mean of 1.9 mm ( $P < .05$ ; Table 1).

An increase in the sagittal position of the mandible at point "Pg" to Nasion perpendicular showed a significant difference with a mean of 1.0 mm ( $P > .05$ ; Table 1).

### Soft-tissue change

A mean 0.9-mm increase in the distance of the most convex point of upper lip to Sn-Pg' line ( $P < .05$ ; Table 2) and a 1.8-mm decrease in the distance of the most convex point of lower lip to Sn-Pg' line were noted after treatment ( $P < .01$ ; Table 2). Furthermore, a negative value of the distance between the most convex points of upper lip and lower lip to Sn-Pg' at the be-

ginning of treatment changed to a positive value ( $P < .001$ ; Table 2), which indicated a dramatic improvement of the concave profile.

### Vertical change

The mandibular plane remained nearly unchanged after active treatment, and the palatal plane and occlusal plane rotated counterclockwise with a mean value of  $1.4^\circ$  ( $P > .05$ ; Table 1) and  $2.9^\circ$  ( $P < .05$ ; Table 1), respectively.

### Case report

A 12-year-old girl presented with an anterior crossbite and a concave profile (Figures 2 through 7). The intraoral examination showed a complete Class III molar relationship on the right side and a super Class III molar relationship on the left side. A crossbite of 15 to 25 was noted. A concave facial profile was present, in combination with a retrusive maxilla and a protrusive mandible with no mandibular displacement. Surgical correction of the skeletal deformity and facial profile was recommended, but the patient refused the procedure and insisted on an orthodontic correction.

A Tip-Edge straight-wire appliance was initiated after extraction of the lower second molars. After 4 months of Class III elastics, the anterior crossbite was corrected. Ten months later, a Class I molar relationship was established. At the end of treatment, the patient showed a straight profile, normal overbite, and overjet. The superimposition of pretreatment and post-treatment cephalogram tracings revealed that the ret-

**TABLE 2.** Results of Traditional Cephalometric Analysis

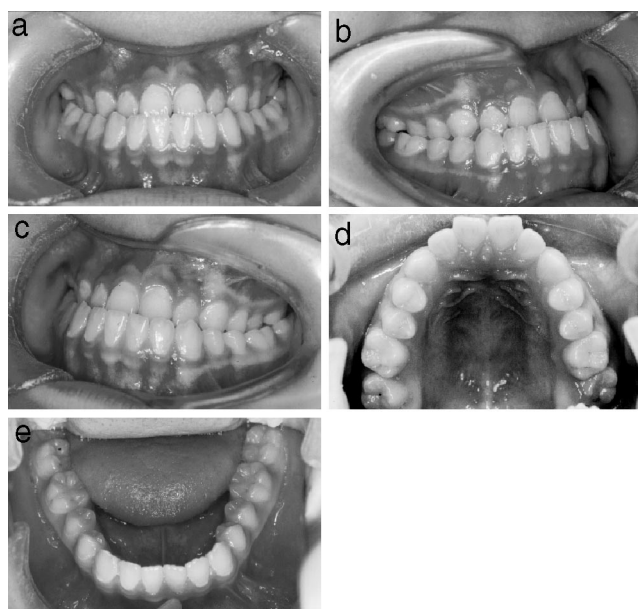
	Pretreatment		Posttreatment		PostTx-PreTx		P Value
	Mean	SD	Mean	SD	Mean	SD	
SNA	81.8	3.4	81.8	2.5	0.0	2.3	NS
SNB	85.5	3.8	84.1	3.2	-1.4	2.4	NS
ANB	-3.6	2.9	-2.3	2.7	1.3	1.9	*
U1-SN	111.8	7.1	113.9	7.4	2.1	7.0	NS
L1-MP	83.8	7.7	71.8	8.0	-12.0	7.0	***
U1-L1	127.2	10.0	134.0	9.5	6.8	10.0	*
UL-SnPg'	5.7	2.1	6.6	2.1	0.9	1.1	*
LL-SnPg'	8.1	2.3	6.3	2.5	-1.8	1.9	**
UL-SnPg'/LL-SnPg'	-2.4	1.4	0.3	0.8	2.7	1.4	***

NS indicates not significant ( $P > .05$ ).

\*  $P < .05$ .

\*\*  $P < .01$ .

\*\*\*  $P < .001$ .

**FIGURE 2.** (a–e) Pretreatment intraoral photographs.

roclination of the lower anterior teeth had changed to a mean of  $11.8^\circ$ . A skeletal Class III tendency remained after the treatment with an ANB of  $-0.68^\circ$ , but the facial profile showed a significant improvement. A follow-up panoramic radiograph showed complete eruption of the lower third molars.

## DISCUSSION

### Mechanism of extraction of lower second molars in correction of skeletal Class III malocclusion

To correct anterior crossbites and normalize molar relationship, the upper arch should move forward and the lower arch backward. Therefore, extractions in the upper arch may be undesirable. Extraction of lower teeth mesial to the first molars might aid correction of

the anterior crossbite, but it might also be unfavorable to the correction of molar relationship. Furthermore, occlusal interlocking of all eight premolars might increase stability after orthodontic therapy, which is crucial to treatment of Class III malocclusion.

Extraction of lower second molars provides more space needed for the anterior teeth to move backward to correct anterior crossbites compared with nonextraction or lower third molars extraction cases. This is also essential for the normalization of molar relationship with no need for “space closure” as in premolar extraction cases. Furthermore, the characteristic of the Tip-Edge technique is a tipping movement of teeth with light and continues forces. The initial force of Class III elastic is relatively light, about 50–60 g. There is no need to use extraoral forces to strengthen the anchorage. In this study, anterior crossbites were corrected, and Class I molar and canine relationships were established in all cases. The lower third molars erupted in place of the second molars, supporting the view that the lower third molars make satisfactory replacements for second molars.<sup>16</sup>

### Consideration when extraction of lower second molars

Some clinicians are critical of lower second molar extraction because the third molars do not always make satisfactory replacements for the lower second molars.<sup>16</sup> Although overeruption of upper second molars and mesial eruption of lower third molars occurred in several cases in this study, these were corrected with minor adjustment, and a good contact relationship was achieved with the lower first molar. Furthermore, numerous clinical evaluation and quantitative studies have proved that normal-sized lower third molars erupt in a good position in the majority of cases. Therefore, elimination of complications for surgical removal of im-

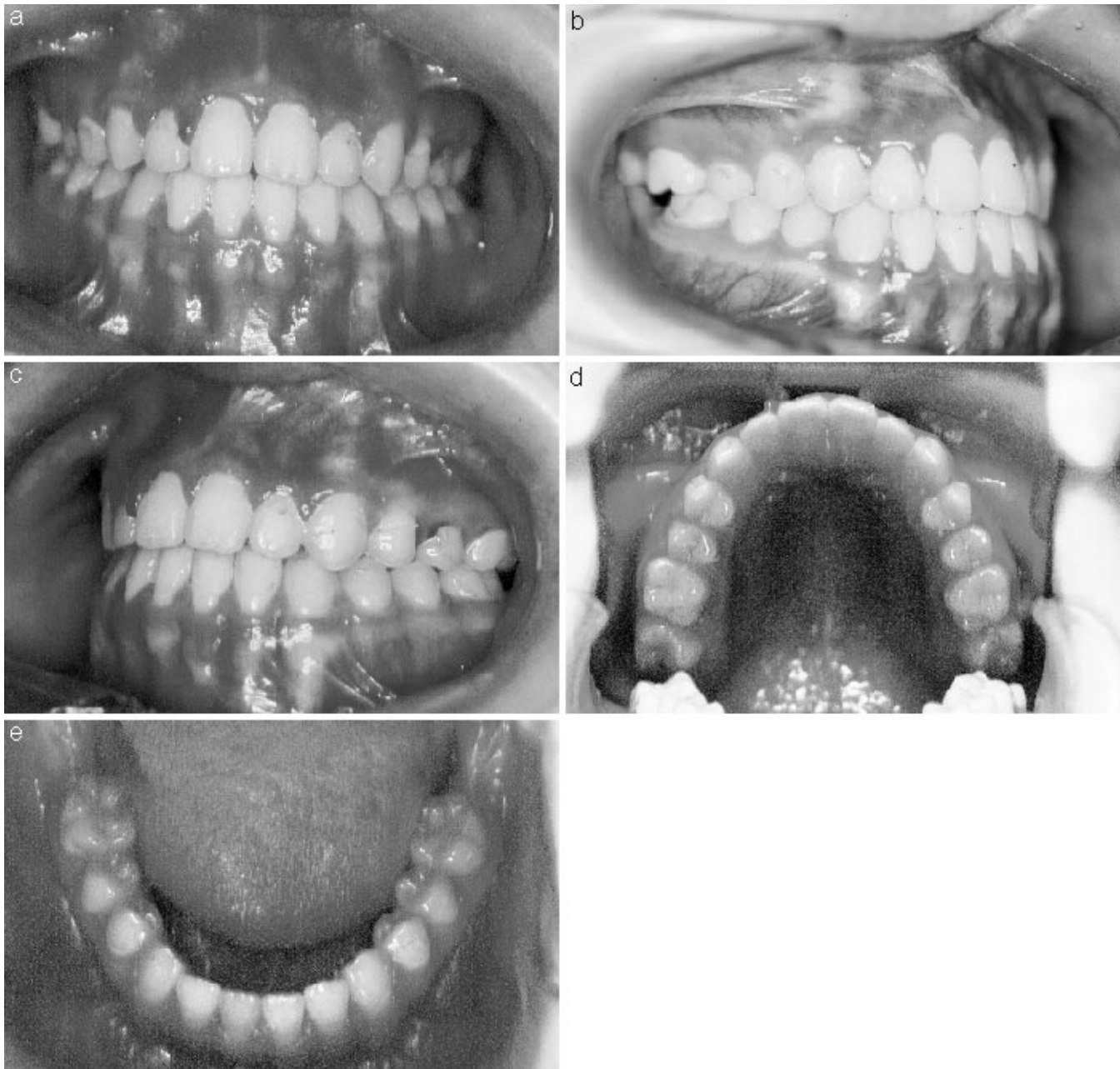


FIGURE 3. (a–e) Posttreatment intraoral photographs.

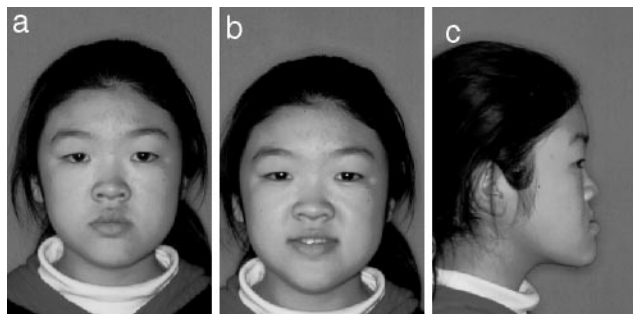


FIGURE 4. (a–c) Pretreatment facial photographs.

pacted third molars is an advantage in favor of lower second molars extractions.<sup>16–19</sup>

The indication for extraction of lower second molars might be (1) severe skeletal Class III malocclusion, (2) super or full Class III molar relationship, and (3) well-aligned upper and lower arch or minor crowding in the lower arch. Extraction of four premolars would not be suitable for these cases because extraction of upper premolars could be disadvantageous for the development of the maxilla. In addition, extraction of lower premolars might worsen the molar relationship. However, extraction of lower third molars might be an alternative

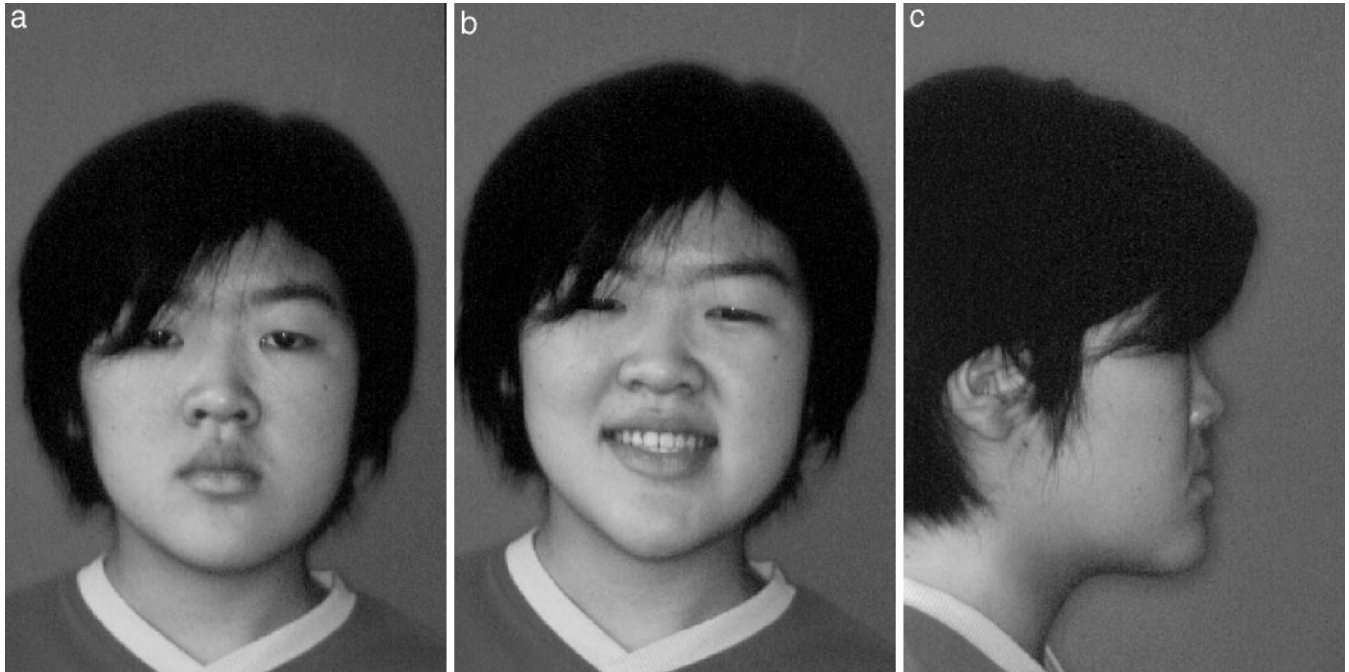


FIGURE 5. (a–c) Posttreatment facial photographs.

therapy in this situation. Obviously, space provided with the extraction of lower third molars is quite limited compared with extraction of lower second molars; this might be critical in the correction of a Class III molar relationship and anterior crossbite.

Extraction of the lower second molars may be a useful treatment option in the management of severe Class III malocclusion. However, such treatment should be carried out after detailed evaluation of third molar position, etc. Although extraction of lower second molars provides enough space to move the lower arch backward compared with the extraction of lower third molars, it has little advantage on relieving crowding in the lower anterior segments. Therefore, to identify the indication of extraction of lower second molars in correction of severe Class III malocclusion is the key for the success of the treatment.

#### **Possible factors contributed to long-term stability of the treatment**

In this study, the eruption of the third molars in proper position with tight intercuspation with upper second molars after extraction of lower second molars in eight cases contributed to the long-term stability of the treatment effect. A favorable growth pattern was established after the active treatment. Although the dental compensatory mechanism in this study needs long-term investigation, good periodontal health creates a favorable perioral environment with normalized oral muscle activity.<sup>20</sup>

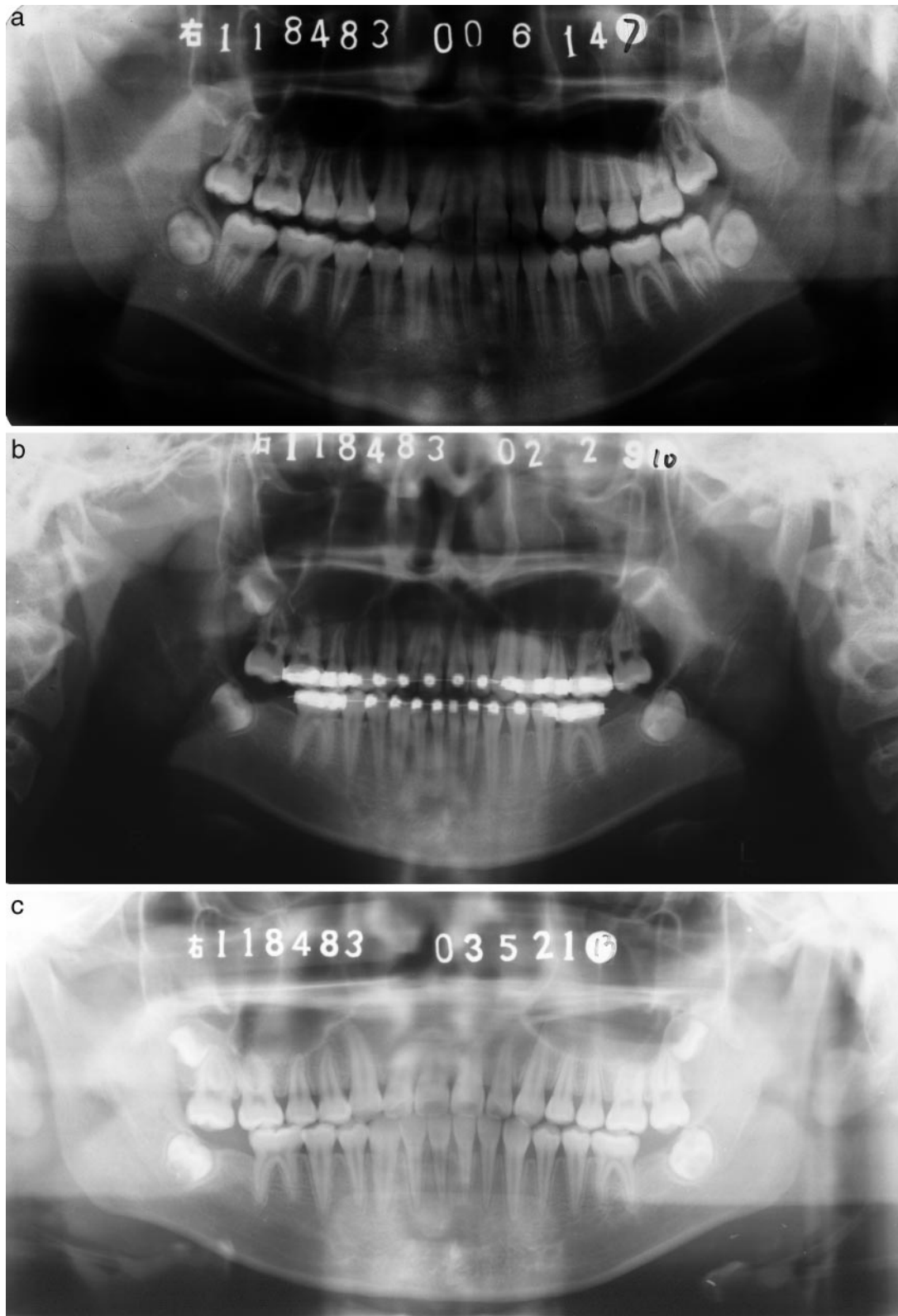
#### **Consideration of third molars**

Extraction of lower second molars provides enough space for distalization of the lower arch and eruption of lower third molars. In this study, lower third molars erupted in suitable position in eight cases either during the treatment or after a 2-year follow-up. Clinical experience has demonstrated that the incidence of impaction of lower third molars is quite low. In addition, the third molars might erupt mesially during the treatment or follow-up period, and this might require minor adjustments to achieve a good contact relationship with the lower first molar.

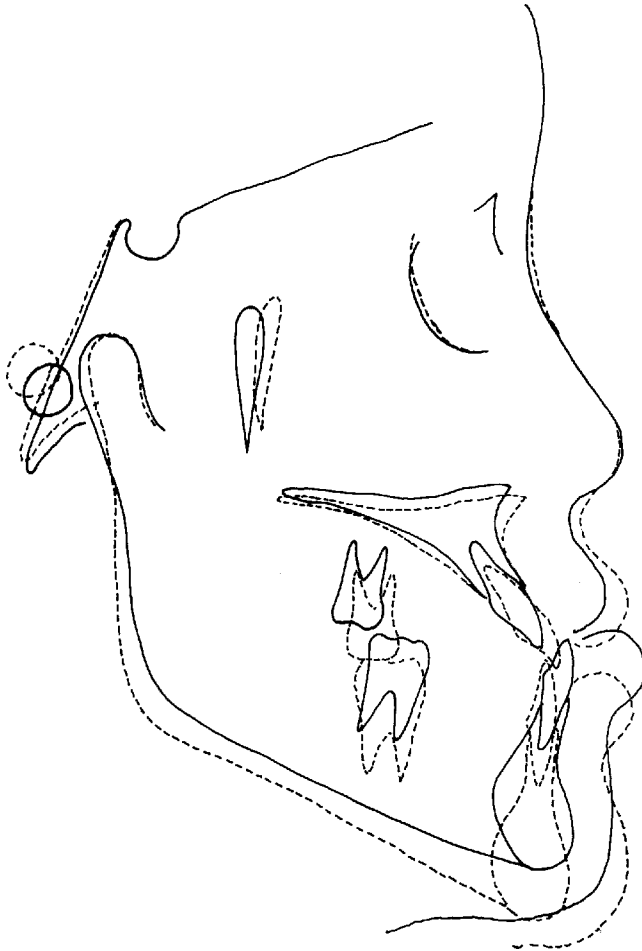
The upper third molars, during their eruption, push the upper dentition forward, which is favorable in correction of Class III malocclusion. However, when the lower third molars take the place of lower second molars, the upper third molars erupt with no opposing teeth, and overeruption should be considered during the current treatment modality. Indeed, extraction of upper third molars should be carried out when lower third molars have erupted into tight intercuspation with upper second molars.

#### **Influence of extraction of lower second molars on soft-tissue profile**

Orthognathic surgery has been demonstrated to successfully modify the skeletal pattern and bring dramatic facial profile change. However, the majority of patients with severe Class III in China are unwilling to accept orthognathic surgery.



**FIGURE 6.** (a) Pretreatment panoramic radiograph. (b) Panoramic radiograph of after extraction of lower second molars. (c) Panoramic radiograph of posttreatment and before eruption of third molars.



**FIGURE 7.** Superimposition of pretreatment and posttreatment cephalometric tracings.

A balanced soft-tissue profile is a desired treatment objective in orthodontics.<sup>1</sup> Although it is impossible to change the position of the nose and chin in severe Class III deformity with orthodontic treatment alone, the change in the position of the upper and lower incisors can influence lip profile. Opinions differ as to whether there is a definite correlation between incisor change and soft-tissue change.<sup>21–27</sup> In this study, the profile was evaluated using a line connecting Sn and soft tissue, Pg, which measures the position of the lips in reference to the nose and chin. With forward movement of the upper lip and backward movement of the lower lip (which was closely related to the labial movement of the upper incisors and lingual movement of the lower incisors), a concave facial profile changed to a straight profile. Furthermore, a positive value (0.3 mm) for the distance difference of upper and lower lips to Sn-Pg' was noted at the end of the treatment, compared with negative one (–2.4 mm) at the beginning of the treatment. This change was due to the inclination change of upper and lower incisors.

We believe this profile change is one of the most

valuable aspects of the study, which makes it acceptable to treat skeletal Class III cases successfully with a nonsurgical orthodontic approach. However, the compensatory mechanism is worthy of further study.

## CONCLUSIONS

- Success in treatment of the some severe Class III deformity in permanent dentition could be achieved with fixed appliance and extraction of lower second molars.
- Fixed appliance in combination with extraction of lower second molars allowed tipping movement of teeth in a larger range and definite and limited skeletal change.
- Remarkable soft-tissue change was noted after extraction of lower second molars, and concave facial profile changed to straight profile.
- Eruption of lower third molar should be the follow-up after extraction of lower second molars, and minor adjustments might be necessary.

## REFERENCES

1. Kerr WJS. Changes in soft tissue profile during the treatment of Class III malocclusion. *Br J Orthod.* 1987;14:243–249.
2. Proffit WR, Fields HW, Ackerman JL, Bailey LT, Tulloch JFC. *Contemporary Orthodontic*, 3rd ed. St Louis, Mo: Mosby-Year Book Inc; 2000:270–272, 276–277, 513–514.
3. Kim YH, Vietas JJ. Anteroposterior dysplasia indicator (APDI): an adjunct to cephalometric differential diagnosis. *Am J Orthod.* 1978;73:619–633.
4. Kim YH. Anterior openbite malocclusion: nature, diagnosis and treatment by means of multiloop edgewise archwire technique. *Angle Orthod.* 1987;57:290–321.
5. Kim YH, Caulfield Z, Chung WN, Chang YI. Overbite depth indicator, anteroposterior dysplasia indicator, combination factor and extraction index. *Int J MEAW.* 1994;1:11–32.
6. Kesling CK. The Tip-Edge concept: eliminating unnecessary anchorage strain. *J Clin Orthod.* 1992;26:165–178.
7. Kesling PC, Rocke RT, Kesling CK. Treatment with Tip-Edge brackets and differential tooth movement. *Am J Orthod Dentofacial Orthop.* 1991;99:387–402.
8. Begg PR, Kesling PC. The differential force method of orthodontic treatment. *Am J Orthod.* 1977;71:1–39.
9. Rodesano AJ. Treatment of Class III malocclusion with the Begg light wire technique. *Am J Orthod.* 1974;65:237–245.
10. Rodesano AJ. Incisor movement in Class III malocclusion treated with the Begg light wire technique. *Am J Orthod.* 1971;60:355–367.
11. Lin JX, Huang JF, Zeng XL. A cephalometric evaluation of hard and soft tissue changes during Class III traction. *Eur J Orthod.* 1985;7:201–204.
12. Xu TM, Lin JX. Bite-opening mechanics as applied in Begg technique. *Br J Orthod.* 1994;21:189–195.
13. Lin JX, Gu Y. Preliminary investigation of nonsurgical treatment of severe skeletal Class III malocclusion in the permanent dentition. *Angle Orthod.* 2003;73:401–410.
14. Pancherz H. The mechanism of Class II correction in Herbst appliance treatment, a cephalometric investigation. *Am J Orthod.* 1982;82:107–113.



15. McNamara JA Jr, Howe RP, Dischinger TG. A comparison of the Herbst and Fränkel appliance in the treatment of Class II malocclusion. *Am J Orthod Dentofacial Orthop.* 1990;98:133–144.
16. Richardson ME, Richardson A. Lower third molar development subsequent to second molar extraction. *Am J Orthod Dentofacial Orthop.* 1993;104:566–574.
17. Cavanaugh JJ. Third molar changes following second molar extraction. *Angle Orthod.* 1985;55:70–76.
18. Lehman R. A consideration of the advantages of second molar extraction in orthodontics. *Eur J Orthod.* 1979;1:119–124.
19. Quinn GW. Extraction of four second molars. *Angle Orthod.* 1985;55:58–69.
20. Björk A. Timing of interceptive orthodontic measures based on stages of maturation. *Trans Eur Orthod Soc.* 1972:61–74.
21. Branoff RS. A roentgenographic cephalometric study of changes in soft tissue profile related to orthodontic treatment. *Am J Orthod.* 1971;60:305–306.
22. Hershey HG. Incisor tooth retraction and subsequent profile changes in postadolescent female patients. *Am J Orthod.* 1972;61:45–54.
23. Holdaway RA. A soft tissue cephalometric analysis and its use in orthodontic treatment planning. Part II. *Am J Orthod.* 1984;85:279–293.
24. Huggis DG, McBride LJ. The influence of the upper incisor position on soft tissue facial profile. *Br J Orthod.* 1975;2:141–146.
25. Oliver BM. The influence of lip thickness and strain on upper lip response to incisor retraction. *Am J Orthod.* 1982;82:41–49.
26. Udee DA. Proportional profile changes concurrent with orthodontic therapy. *Am J Orthod.* 1964;50:421–434.
27. Wisth PJ. Soft tissue response to upper incisor retraction in boys. *Br J Orthod.* 1974;1:199–204.