

## ORIGINAL ARTICLE

# Direct immunofluorescence analysis of oral Tzanck smears for pemphigus vulgaris: A diagnostic test

Wenxiu He | Kaiyi Li | Xiaosheng Hu | Hong Hua  | Pan Wei

Department of Oral Medicine, Peking University School and Hospital of Stomatology, National Center of Stomatology, National Clinical Research Center for Oral Diseases, National Engineering Laboratory for Digital and Material Technology of Stomatology, Beijing Key Laboratory of Digital Stomatology, Research Center of Engineering and Technology for Computerized Dentistry Ministry of Health, NMPA Key Laboratory for Dental Materials, Beijing, China

**Correspondence**

Hong Hua, Pan Wei Department of Oral Medicine, Peking University School and Hospital of Stomatology, National Center of Stomatology, National Clinical Research Center for Oral Diseases, National Engineering Laboratory for Digital and Material Technology of Stomatology, Beijing Key Laboratory of Digital Stomatology, Research Center of Engineering and Technology for Computerized Dentistry Ministry of Health, NMPA Key Laboratory for Dental Materials, No.22, Zhongguancun South Avenue, Haidian District, Beijing, 100081, China.

Emails: honghua1968@aliyun.com; dent\_wei@163.com

**Funding information**

New Clinical Techniques and Therapies of Peking University School and Hospital of Stomatology, Grant/Award Number: PKUSSNCT-18A01 and PKUSSNCT-19A04; National Program for Multidisciplinary Cooperative Treatment on Major Diseases, Grant/Award Number: PKUSSNMP-202019

**Abstract**

**Background:** Pemphigus vulgaris (PV) is a rare and potentially fatal autoimmune blistering disease. Direct immunofluorescence (DIF) and histopathological analysis are crucial methods for PV diagnosis, but oral tissue biopsy is difficult to perform because of the fragile characteristics of the oral mucosa. However, no well-designed diagnostic studies addressing the validity of DIF analysis of oral Tzanck smears for the diagnosis of PV exist. We aimed to design a diagnostic test based on DIF analysis combined with oral Tzanck smears and evaluate its diagnostic accuracy for PV.

**Methods:** We enrolled 81 patients with oral erosive lesions, of whom 41 patients had PV and 40 were non-PV controls. Oral Tzanck smears were obtained from oral mucosal lesions and observed under a fluorescence microscope after fixing and fluorescence staining. The diagnostic efficacy indexes including sensitivity, specificity, predictive value, Youden index, diagnostic odds ratio, and likelihood ratio were calculated.

**Results:** Of the 41 PV patients, 36 showed DIF-positive findings for oral Tzanck smears, and all 36 DIF-positive PV patients showed IgG and/or C3 deposition, with seven also showing IgA and/or IgM positivity. None of the non-PV controls showed DIF positivity. The sensitivity and specificity of DIF analysis with oral Tzanck smears were 87.80% and 100%, respectively. The area under the receiver operator characteristic curve (ROC) was 0.939, with the test demonstrating significantly high diagnostic efficacy.

**Conclusion:** DIF analysis of oral Tzanck smears is a minimally invasive and easy-to-operate technique that can assist the rapid and accurate diagnosis of PV in dental clinic.

**KEYWORDS**

autoimmune diseases, diagnostic test, direct immunofluorescences, oral Tzanck smears, pemphigus vulgaris

## 1 | INTRODUCTION

Pemphigus is a severe autoimmune blistering disease that frequently involves the skin and mucosa, with pemphigus vulgaris (PV) being the

most common form.<sup>1</sup> In 50%–80% of the patients, the initial symptoms of PV are oral mucosal lesions with or without skin lesions, and almost all PV patients present with oral mucosal lesions.<sup>2–4</sup> Thus, dentists play an important role in the early diagnosis and treatment of PV.

The incidence of PV is 2.06–4.7 per million people per year in Asia.<sup>5,6</sup> PV mostly occurs in patients aged 45–65 years, with a male-to-female ratio of 1:1.1–1:1.7.<sup>4,7,8</sup> The pathogenesis of PV involves the direct targeting of the intercellular desmosomal adhesion molecule desmoglein (Dsg) 1 and 3 by autoantibodies, which cause the loss of cell-cell adhesion between keratinocytes and thereby result in acantholysis.<sup>9</sup>

Oral corticosteroids are one of the first-line therapeutic agents for PV; however, long-term oral corticosteroid use is associated with many adverse effects.<sup>10,11</sup> Furthermore, even with systemic treatment, the mortality rate of PV patients remains 2.4 times higher than that of the general population, of which more than 70% of the deaths are related to the side effects of corticosteroids.<sup>5,12,13</sup> Thus, precise and early diagnosis of PV is essential for disease treatment and management.

The diagnosis of PV is based on the clinical presentation, histopathological manifestations, serologic detection, and direct immunofluorescence (DIF), of which DIF and histopathological findings are crucial and essential for diagnosis and are routinely applied in dermatology clinic.<sup>11,12,14</sup> However, DIF and histopathological analysis require uninvolved peri-lesional oral mucosal biopsy, which is prone to frictional disruption and erosion, leading to difficulties for the dentists to obtain oral mucosal tissues for DIF.<sup>15</sup> To date, a few studies using the combination of DIF analysis and oral Tzanck smears for diagnosis of PV have been reported.<sup>16–18</sup> However, the studies were limited by small sample size or not strictly designed as the typical diagnostic test.

Therefore, this study was designed to evaluate the diagnostic accuracy of DIF analysis of oral Tzanck smears in PV, and to explore the feasibility of this rapid, easy-to-operate, and effective diagnostic approach for clinical application.

## 2 | MATERIALS AND METHODS

### 2.1 | Study design

This study aimed to evaluate the diagnostic efficacy of DIF analysis with oral Tzanck smears for the diagnosis of PV. The study was designed according to the Standards for Reporting Diagnostic Accuracy (STARD) statement.<sup>19</sup> Tzanck smear collection and DIF evaluations were performed on all patients presenting with oral mucosal erosions.

### 2.2 | Diagnostic criteria for PV

The criteria were based on the Japanese guidelines for the management of pemphigus, published in 2014.<sup>14</sup> The diagnostic criteria for PV were as follows: (A) blisters or erosions on mucosal areas, with or without skin lesions; (B) histopathological features of suprabasal split and acantholysis; (C) detection of anti-Dsg IgG autoantibodies by enzyme-linked immunosorbent assay (ELISA) or deposition of IgG

autoantibodies against the epithelial cell surface on indirect immunofluorescence (IIF).

Diagnosis was performed by oral medicine and pathology specialists, based on the diagnostic criteria; the specialists were blinded to the results of DIF analysis with oral Tzanck smears.

### 2.3 | Inclusion and exclusion criteria

Patients with oral mucosal erosions who were over 18 years of age and volunteered to participate and cooperate with the investigators were included in the study. The included subjects were allocated to the PV or non-PV control groups, based on diagnosis of PV or diseases other than PV, such as pemphigoid and erythema multiforme.

Patients were excluded if they were (A) using topical/systemic corticosteroids or immunosuppressors prior to participation; (B) pregnant or lactating women or minors (<18 years of age); or (C) unable to cooperate with investigators for any reason.

### 2.4 | Participant enrollment

Eighty-one patients presenting with oral mucosal erosions at the Department of Oral Medicine, Peking University School and Hospital of Stomatology from March 2018 to January 2021 were included. All participants were enrolled based on the inclusion and exclusion criteria with their informed consent prior to the inclusion in this study, with 41 patients allocated to the PV group and 40 to the non-PV group according to the diagnostic criteria for PV. Clinical, histopathological, and ELISA, or IIF examinations were performed for each patient.

### 2.5 | Sample collection and processing

The roof of the oral lesions was carefully removed, and the base of the erosive lesions in the oral mucosa was scraped in all patients. The samples were collected following the standard operating procedure. The obtained oral Tzanck cells were spread as a thin layer on five microscope slides and air-dried. After fixing in acetone for 1 min, the five slides were stained with FITC anti-human IgG (ab6854, diluted 1:200; Abcam), FITC anti-C3c antibody (ab4212, diluted 1:1000; Abcam), FITC anti-human IgM (ab97204, diluted 1:200; Abcam), FITC anti-human IgA (ab97219, diluted 1:200; Abcam), and phosphate-buffered saline (PBS) (0.01 M, pH 7.4) at room temperature for 30 min, washed three times with PBS for 5 min, and washed with distilled water for 5 min. Air-dried slides were immediately observed under a fluorescence microscope (NIKON ECLIPSE 80i, 450–490 nm). The results were recorded as positive if circular green fluorescence surrounding the oral Tzanck cells was captured. Two researchers (HWX and WP) read and recorded the results independently; they were blinded for the final diagnosis ( $\kappa > 0.8$ ), and the

third senior expert (HH) was asked to discuss and adjudicate when the two researchers disagreed.

## 2.6 | Ethics

This study was approved by the Ethics Committee of the Peking University School of Stomatology (PKUSSIRB-201840186), with the registration number ChiCTR2100042024. All participants signed informed consent forms before participation.

## 2.7 | Statistical analysis

Statistical analyses were performed using SPSS software (SPSS version 20.0; SPSS, Inc.). The formula for sample size determination for diagnostic studies recommended a sample size of 76 participants, with 38 each in the PV and control groups.<sup>20</sup> The chi-square test and *t* test were used to evaluate gender- and age-related differences between the two groups. Sensitivity, specificity, predictive value, Youden index, diagnostic odds ratio, and likelihood ratio were calculated to determine the efficacy of the diagnostic test. The receiver operator characteristic curve (ROC) was constructed, and the area under the ROC curve (AUC) was calculated.

## 3 | RESULTS

### 3.1 | Demographic and clinical characteristics

The general information of all the patients was recorded, including name, age, gender, and clinical manifestation. Data from 41 patients in the PV group and 40 patients in the non-PV group were analyzed. The two groups showed no significant differences in relation to gender (male/female, 16/25 vs. 15/25, *p* = 0.89) and age ( $53.80 \pm 10.47$  vs.  $56.36 \pm 14.70$  years, *p* = 0.37) (Table 1).

### 3.2 | Clinical features of the PV group

The PV group included 23 and 18 cases with mucosal-dominant and mucocutaneous variants, respectively, with no statistically significant differences in the occurrence of Dsg3 and Dsg1 autoantibodies between the two subgroups (*p* > 0.05) (Table 1). The most commonly involved sites in the oral cavity were the bilateral buccal mucosa, tongue, and inner side of the lips with enanthema and erosions. The clinical features of the oral cavity were shown in Figure 1.

DIF analysis of oral Tzanck smears under the fluorescence microscope manifests as circular green fluorescence surrounding the cells, appearing as a string-like or grape-like fluorescence cluster when the Tzanck cells form dense clumps (Figure 2).

### 3.3 | Autoantibody subtypes

Among the 41 patients in the PV group, 36 were positive for DIF of the oral Tzanck smear, and all the 36 patients showed IgG- and/or C3-positive deposition, with 7 patients (19.4%) also showing IgM- and/or IgA-positive findings. The details are presented in Table 2.

### 3.4 | Diagnostic efficacy

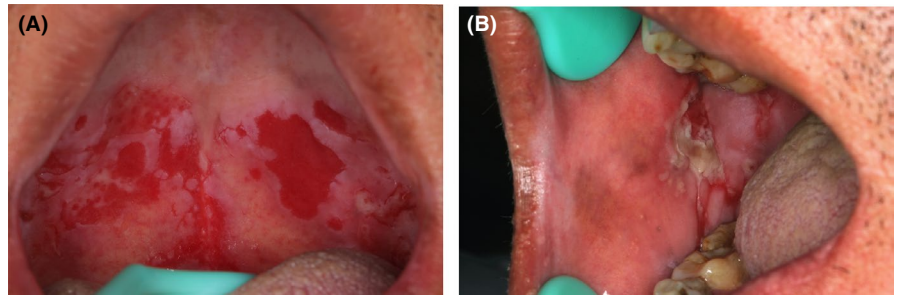
In the PV group, 87.8% (36/41) showed positivity and 12.2% (5/41) showed false-negative findings for DIF of the oral Tzanck smears; in the non-PV group, all 40 patients showed negative findings (Table 3). The sensitivity and specificity of DIF analysis with oral Tzanck smears were 87.80% and 100%, respectively. Other parameters, including predictive value, Youden index, diagnostic odds ratio, and likelihood ratio, to determine the diagnostic efficacy are shown in Table 4. The ROC curve of DIF analysis of oral Tzanck smears was very close to the top-left chart corner,

TABLE 1 Demographic and clinical features

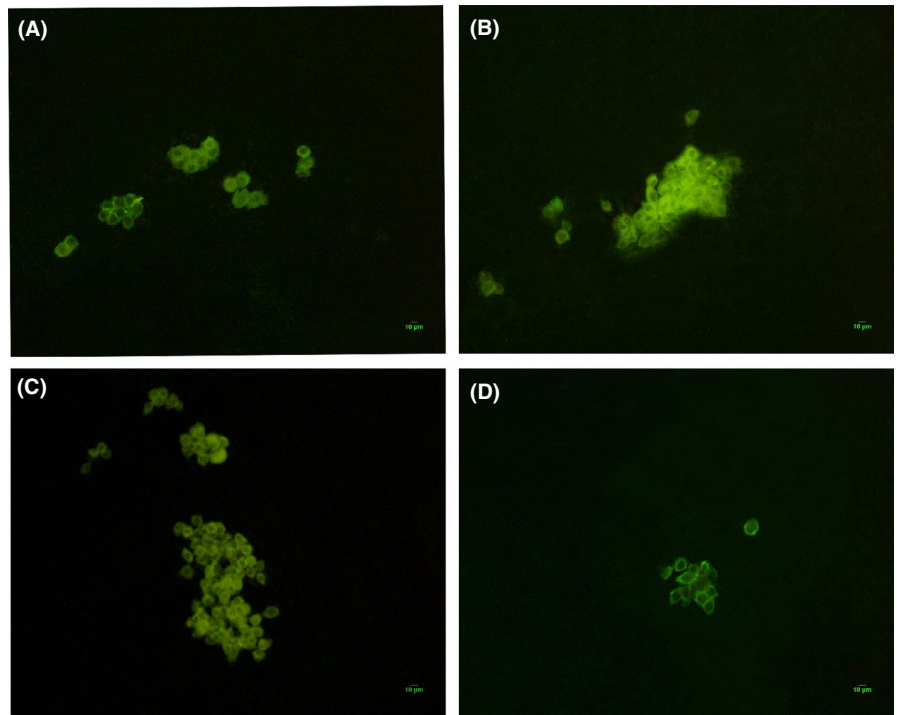
	Gender (Male/ Female)	Age	ELISA	
			Dsg3 (U/ml)	Dsg1 (U/ml)
PV group (n = 41)	16/25	53.80 ± 10.47	162.75 ± 44.45 (n = 38)	47.57 ± 34.94 (n = 27)
Mucosal-dominant variants (n = 23)	7/16	54.13 ± 10.86	158.64 ± 53.82 (n = 21)	42.05 ± 29.35 (n = 13)
Mucocutaneous variants (n = 18)	9/9	53.39 ± 10.23	167.82 ± 30.00 (n = 17)	52.69 ± 39.85 (n = 14)
Non-PV group (n = 40)	15/25	56.35 ± 14.70	-	-
MMP (n = 29)	9/20	57.41 ± 13.21	-	-
LPP (n = 2)	2/0	72.50 ± 10.61	-	-
EM (n = 7)	4/3	46.86 ± 16.67	-	-
EOLP (n = 2)	0/2	58.00 ± 24.04	-	-

Abbreviations: Dsg, Desmoglein; ELISA, Enzyme-linked immunosorbent assay; EM, Erythema multiforme; EOLP, Erosive oral lichen planus; LPP, Lichen planus pemphigoid; MMP, Mucous membrane pemphigoid; PV, Pemphigus vulgaris.

**FIGURE 1** The clinical features of the oral cavity of PV patients. (A) and (B) showed the lesions of the soft palate and buccal mucosa, respectively. Abbreviations: PV, Pemphigus vulgaris



**FIGURE 2** The positive findings of DIF analysis of oral Tzanck cells observed under the fluorescence microscope. (A), (B), (C), and (D) showed C3-, IgG-, IgM-, and IgA-positive deposition, respectively. Abbreviations: DIF, Direct immunofluorescence; C3, Complement 3; IgG, Immunoglobulin G; IgM, Immunoglobulin M; IgA, Immunoglobulin A



**TABLE 2** DIF analysis of oral Tzanck smears

	DIF analysis of oral Tzanck smears		
	PV group (n = 41)	Non-PV group (n = 40)	Total (n)
Positive (n)	36	0	36
Negative (n)	5	40	45
Total (n)	41	40	81

Abbreviations: DIF, Direct immunofluorescence; PV, Pemphigus vulgaris.

with an AUC of 0.939, indicating its superior diagnostic efficacy. (Figure 3).

### 3.5 | Cost analysis

The hands-on time and total turnaround time of DIF analysis with oral Tzanck smears were 5 and 75 min, respectively; the cost of materials was CNY 40 per case (Table 5).

### 3.6 | Adverse events

All patients experienced no pain or only slight pain with minor bleeding during processing of the Tzanck smear of oral mucosal erosions. No severe adverse events were observed in this study.

## 4 | DISCUSSION

Pemphigus is a severe autoimmune blistering disease associated with a mortality risk twice that in the normal population.<sup>2</sup> For PV, the oral cavity is the first site involved in 50%–80% of patients, and almost all patients show oral lesions.<sup>3</sup> Thus, dentists play an important role in the early and precise diagnosis of PV.

According to the diagnostic guidelines and algorithms for PV published in recent years, DIF and pathological analysis of biopsy specimens are critical in confirming diagnosis.<sup>2,11,14,21,22</sup> However, peri-lesional biopsy on the uninvolved mucosa in the oral cavity is difficult, especially for the gingiva, palate, and the floor of the mouth.<sup>23</sup> Moreover, DIF analysis of biopsy specimens is associated

TABLE 3 Diagnostic efficacy of DIF analysis of oral Tzanck smears for pemphigus vulgaris

Sensitivity (%)		Specificity (%)		PLR		NLR		PPV (%)		NPV (%)		
Point value	95% CI	Point value	95% CI	Youdenindex	Point value	95% CI	Point value	95% CI	Point value	95% CI	Point value	
87.80	73.80–95.92	100.00	91.19–100.00	0.88	-	-	0.12	5.36–27.73	100.00	90.26–100.00	88.89	75.95–96.29

Abbreviations: 95% CI, 95% Confidence interval; DIF, Direct immunofluorescence; NLR, Negative likelihood ratio; NPV, Negative predictive value; PLR, Positive likelihood ratio; PPV, Positive predictive value.

TABLE 4 Autoantibody subtypes of the 36 DIF-positive patients diagnosed by Tzanck smear in PV group

Autoantibody subtypes				
IgG	IgA	IgM	C3	n
+	-	-	-	8
-	-	-	+	11
-	-	+	+	1
+	-	-	+	10
+	-	+	+	2
+	+	-	+	1
+	+	+	+	3
Total				36

Abbreviations: -, Negative; +, Positive; C3, Complement 3; DIF, Direct immunofluorescence; IgA, Immunoglobulin A; IgG, Immunoglobulin G; IgM, Immunoglobulin M; PV, Pemphigus vulgaris.

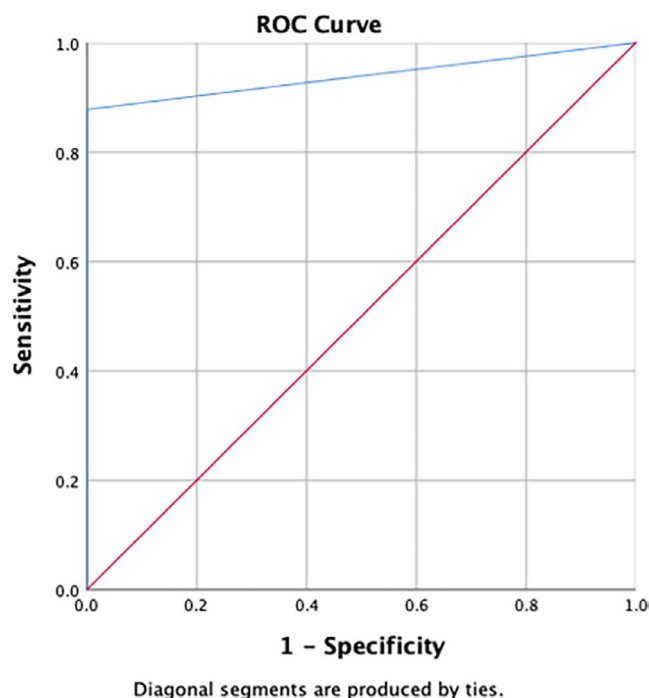


FIGURE 3 The ROC curve of DIF analysis of oral Tzanck smears. Abbreviations: DIF, Direct immunofluorescence; ROC, The receiver operator characteristic curve

with stringent requirements related to biopsy tissues, equipment, and professionals, which limits the rapid and convenient application of this technique in clinical practice. Considering these challenges, we combined DIF analysis with oral Tzanck smears and evaluated the potential value of this approach for rapid and precise diagnosis of PV. DIF analysis of oral Tzanck smears is a painless approach that is less invasive than biopsy and reveals the immunological characteristics of green fluorescence surrounding acantholytic cells.<sup>17,18,24</sup>

**TABLE 5** Cost analysis of DIF analysis with oral Tzanck smears

	Hands-on time (min)	Total turnaround time (h)	Cost of materials (CNY)
DIF analysis with oral Tzanck smears	5	1.25	40
DIF of intraoral biopsy	30	72	420
Histopathological analysis	30	96	560

Abbreviations: DIF, Direct immunofluorescence.

Thus, in theory, DIF analysis of oral Tzanck smears shows good application prospects in clinical practice.

In this study, we evaluated the diagnostic efficacy of DIF analysis of oral Tzanck smears for the diagnosis of PV in clinical practice. The diagnostic efficacy of DIF analysis of oral Tzanck smears was significantly high, with a sensitivity of 87.80% and specificity of 100%, and an AUC of 0.939, indicating its high diagnostic accuracy.<sup>25</sup> In comparison with ELISA, which shows a sensitivity and specificity of 81.6% and 93.9%, DIF analysis of oral Tzanck smears showed much higher diagnostic efficacy for PV and illustrated the specific subtypes of autoantibodies.<sup>26</sup> All 36 DIF-positive patients showed IgG and/or C3 deposition, of which 7 also showed IgA and/or IgM positivity, indicating that IgG and/or C3 are the main antibody subtypes for PV diagnosis. In comparison with IIF, which showed sensitivity and specificity of 82.3% and 95.6%, DIF analysis of oral Tzanck smears showed advantages both in diagnostic accuracy and in terms of invasiveness and cost-effectiveness for clinical application.<sup>26</sup> In addition, while the results of IIF may be affected by substrates, DIF analysis of oral Tzanck smears was less likely to be influenced by objective conditions.<sup>27</sup> BIOCHIP has been recently identified as a new multiplex tool for the diagnosis of autoimmune bullous diseases with the advantages of rapid detection and less invasion, although the diagnostic accuracy of 60.9% for PV was somewhat lower than that of DIF analysis of oral Tzanck smears.<sup>28</sup> Moreover, DIF analysis of oral Tzanck smears was a cost-effective and time-efficient method compared with DIF of biopsy and histopathological analysis.

Among the 41 patients with PV, 5 showed false-negative findings in DIF analysis of oral Tzanck smears, and there were several reasons for the false-negative findings. For PV patients with mild disease severity, the reaction of autoantibodies and antigens was bound weakly, leading to weak expression of immunofluorescence. Moreover, the collection of oral Tzanck cells by scraping was also dependent on the technique of the researchers.

This study had some limitations. First, although the number of participants had reached the recommended sample size calculated according to the formula for diagnostic studies, more large-sample studies may be warranted to further validate our findings. Second, the technique for collection and processing of oral Tzanck smear specimens could influence the results, thus emphasizing the standard operating procedure and the importance of high-quality sample processing procedures would be necessary for the successful use of this technique in PV diagnosis in clinical practice.

## 5 | CONCLUSION

In conclusion, DIF analysis of oral Tzanck smears could serve as a rapid, economical, and minimally invasive diagnostic tool for accurate diagnosis of PV in clinical practice.

## ACKNOWLEDGEMENT

The authors sincerely thank all participants for their collaboration. This study was supported by the Program for New Clinical Techniques and Therapies of Peking University School and Hospital of Stomatology (PKUSSNCT-18A01 and PKUSSNCT-19A04) and National Program for Multidisciplinary Cooperative Treatment on Major Diseases (PKUSSNMP-202019).

## CONFLICTS OF INTEREST

The authors declare no potential conflicts of interest.

## AUTHOR CONTRIBUTIONS

**Wenxiu He:** Data curation; Formal analysis; Investigation; Resources; Software; Validation; Visualization; Writing-original draft. **Kaiyi Li:** Investigation; Validation. **Xiaosheng Hu:** Investigation; Validation. **Hong Hua:** Conceptualization; Funding acquisition; Methodology; Project administration; Writing-review & editing. **Pan Wei:** Formal analysis; Funding acquisition; Methodology; Project administration; Supervision; Writing-review & editing.

## DATA AVAILABILITY STATEMENT

The data that support the findings of this study are available from the corresponding author upon reasonable request.

## ORCID

Hong Hua  <https://orcid.org/0000-0003-1198-508X>

## REFERENCES

- Schmidt E, Kasperkiewicz M, Joly P. Pemphigus. *Lancet*. 2019;394(10201):882-894.
- Rashid H, Lamberts A, Diercks GFH, et al. Oral lesions in autoimmune bullous diseases: an overview of clinical characteristics and diagnostic algorithm. *Am J Clin Dermatol*. 2019;20(6):847-861. 10.1007/s40257-019-00461-7
- Buonavoglia A, Leone P, Dammacco R, et al. Pemphigus and mucous membrane pemphigoid: an update from diagnosis to therapy. *Autoimmun Rev*. 2019;18(4):349-358.
- Hübner F, Recke A, Zillikens D, Linder R, Schmidt E. Prevalence and age distribution of pemphigus and pemphigoid diseases in Germany. *J Eur Acad Dermatol Venereol*. 2016;136:2495-2498.
- Huang YH, Kuo CF, Chen YH, Yang YW. Incidence, mortality, and causes of death of patients with pemphigus in Taiwan: a nationwide population-based study. *J Invest Dermatol*. 2012;132(1):92-97.

6. Lee YB, Lee JH, Lee SY, et al. Incidence and death rate of pemphigus vulgaris and pemphigus foliaceus in Korea: a nationwide, population-based study (2006–2015). *J Dermatol*. 2018;45(12):1396-1402.
7. Jelti L, Cordel N, Gillibert A, et al. Incidence and mortality of pemphigus in France. *J Invest Dermatol*. 2019;139:469-473.
8. Kridin K. Pemphigus group: overview, epidemiology, mortality, and comorbidities. *Immunol Res*. 2018;66(2):255-270.
9. Hammers CM, Stanley JR. Mechanisms of disease: pemphigus and bullous pemphigoid. *Annu Rev Pathol*. 2016;11:175-197.
10. Bystryj JC, Steinman NM. The adjuvant therapy of pemphigus. an update. *Arch Dermatol*. 1996;132(2):203-212.
11. Murrell DF, Peña S, Joly P, et al. Diagnosis and management of pemphigus: Recommendations of an international panel of experts. *J Am Acad Dermatol*. 2020;82(3):575-85.
12. Harman KE, Brown D, Exton LS, et al. British association of dermatologists' guidelines for the management of pemphigus vulgaris 2017. *Br J Dermatol*. 2017;177(5):1170-1201.
13. Kridin K, Sagi SZ, Bergman R. Mortality and cause of death in patients with pemphigus. *Acta Derm Venereol*. 2017;97(5):607-611.
14. Amagai M, Tanikawa A, Shimizu T, et al. Japanese guidelines for the management of pemphigus. *J Dermatol*. 2014;41(6):471-486.
15. Patel AN, Simpson RC, Cohen SN. In a patient with an immunobullous disorder, is transportation of the skin biopsy in normal saline adequate for direct immunofluorescence analysis? a critically appraised topic. *Br J Dermatol*. 2013;169(1):6-10.
16. Laskaris G, Papanicolaou S, Angelopoulos A. Immunofluorescent study of cytologic smears in oral pemphigus: a simple diagnostic technique. *Oral Surg Oral Med Oral Pathol*. 1981;51(5):531-534.
17. Aithal V, Kini U, Jayaseelan E. Role of direct immunofluorescence on tzanck smears in pemphigus vulgaris. *Diagn Cytopathol*. 2007;35(7):403-407.
18. Brito MMC, Tarquinio DC, Arruda D, Costa RS, Roselino AM. Tzanck smears: an old but useful diagnostic tool. *An Bras Dermatol*. 2009;84(4):431-433.
19. Bossuyt PM, Reitsma JB, Bruns DE, et al. STARD 2015: an updated list of essential items for reporting diagnostic accuracy studies. *BMJ*. 2015;351:h5527.
20. Flahault A, Cadilhac M, Thomas G. Sample size calculation should be performed for design accuracy in diagnostic test studies. *J Clin Epidemiol*. 2005;58(8):859-862.
21. Kershenovich R, Hodak E, Mimouni D. Diagnosis and classification of pemphigus and bullous pemphigoid. *Autoimmun Rev*. 2014;13(4-5):477-481.
22. Hertl M, Jedlickova H, Pemphigus KS, et al. S2 Guideline for diagnosis and treatment-guided by the European dermatology forum (EDF) in cooperation with the European academy of dermatology and venereology (EADV). *J Eur Acad Dermatol Venereol*. 2015;29(3):405-414.
23. Carey B, Joshi S, Abdelghani A, Mee J, Andiappan M, Setterfield J. The optimal oral biopsy site for diagnosis of mucous membrane pemphigoid and pemphigus vulgaris. *Br J Dermatol*. 2020;182(3):747-753.
24. Mignogna MD, Lo Muzio L, Zeppa P, Ruocco V, Bucci E. Immunocytochemical detection of autoantibody deposits in tzanck smears from patients with oral pemphigus. *J Oral Pathol Med*. 1997;26(6):254-257.
25. Swets JA. Measuring the accuracy of diagnostic systems. *Science*. 1988;240:1285-1293.
26. Van de Gaer O, de Haes P, Bossuyt X. Detection of circulating anti-skin antibodies by indirect immunofluorescence and by ELISA: a comparative systematic review and meta-analysis. *Clin Chem Lab Med*. 2020;58(10):1623-1633.
27. Zhou T, Fang S, Li C, Hua H. Comparative study of indirect immunofluorescence, enzyme-linked immunosorbent assay, and the tzanck smear test for the diagnosis of pemphigus. *J Oral Pathol Med*. 2016;45:786-790.
28. Yang A, Xuan R, Melbourne W, Tran K, Murrell DF. Validation of the BIOCHIP test for the diagnosis of bullous pemphigoid, pemphigus vulgaris and pemphigus foliaceus. *J Eur Acad Dermatol Venereol*. 2020;34(1):153-160.

**How to cite this article:** He W, Li K, Hu X, Hua H, Wei P. Direct immunofluorescence analysis of oral Tzanck smears for pemphigus vulgaris: A diagnostic test. *J Oral Pathol Med*. 2021;50:1050-1056. <https://doi.org/10.1111/jop.13239>