

Fluorescence staining vs. routine KOH smear for rapid diagnosis of oral candidiasis—A diagnostic test

Lijun Hu^{1,2}  | Peiru Zhou¹ | Weiwei Zhao¹ | Hong Hua¹ | Zhimin Yan¹ 

¹Department of Oral Medicine, Peking University School and Hospital of Stomatology, National Engineering Laboratory for Digital and Material Technology of Stomatology, Beijing, China

²Department of Oral Medicine, The Affiliated Stomatology Hospital, Zhejiang University School of Medicine, Key Laboratory of Oral Biomedical Research of Zhejiang Province, Zhejiang University School of Stomatology, Hangzhou, China

Correspondence

Zhimin Yan, Department of Oral Medicine, Peking University School and Hospital of Stomatology, 22 South Zhongguancun Avenue, Haidian District, Beijing 100081, China.

Email: yzhimin96@163.com

Funding information

Peking University School and Hospital of Stomatology, Grant/Award Number: PKUSSNCT-17A02; Natural Science Foundation of China, Grant/Award Number: 81570985

Abstract

Objective: A diagnostic test was designed to evaluate the accuracy and applicability of fluorescence staining with fluorescein-labelled chitinase versus routine 10% potassium hydroxide (KOH) smear for rapid diagnosis of oral candidiasis.

Methods: In total, 124 subjects with suspected oral candidiasis symptoms/signs were sequentially enrolled in this study. The diagnostic efficacy indexes (sensitivity, specificity, Youden index, predictive value, likelihood ratio, diagnostic odds ratio, diagnostic accuracy and area under the curve [AUC]) were compared between 10% KOH smear and fluorescence staining.

Results: The sensitivity (85.48% vs. 64.52%) and specificity (91.94% vs. 72.58%) of fluorescence staining were higher than those of KOH smear. The AUC of fluorescence staining (0.887) was remarkably higher than that of 10% KOH smear (0.685), demonstrating that the diagnostic efficacy of fluorescence staining is significantly higher than that of KOH smear ($p = .0005$). Furthermore, fluorescence staining showed higher sensitivity than that of KOH smear (84.75% vs. 62.71%) in diagnosis of erythematous type oral candidiasis, which is the most common type and the type most challenging to differentially diagnose.

Conclusion: The advantages of fluorescence staining with fluorescein-labelled chitinase in rapid diagnosis of oral candidiasis and its ease of operation suggest its potential use in clinical practice.

KEYWORDS

diagnosis, fluorescence staining, oral candidiasis, rapid

1 | INTRODUCTION

In recent years, fluorescence staining has attracted more attention due to its potential for rapid diagnosis of fungal infections. Accumulated evidence has shown that fluorescence staining has good diagnostic efficacy in diagnosis of tinea unguium, tinea pedis, tinea capitis, corneal fungal infection and deep fungal infections (Chen et al., 2016; He et al., 2018; Higareda-Almaraz et al., 2016). The mechanism involves binding of fluorescent dyes, including

calcofluor white (CFW), fluorescein isothiocyanate (FITC) and acridine orange (AO), among others (Chick & Behar, 1961; Moussa, Tayel, & Al-Turki, 2013; Sanketh, Patil, & Rao, 2016), to cellulose or chitin in the cell wall of the fungal through a chemical bond (Roncero & Duran, 1985; Roncero, Valdivieso, Ribas, & Duran, 1988). In recent few years, another fluorescent reagent, fluorescently labelled chitinase, has been found to specifically and quickly bind to cellulose or chitin in the fungal cell wall with high affinity (Luo et al., 2017). The hyphae or spores emit bright blue/green fluorescence, which makes

the fungal morphology clear under a fluorescence microscope using 340 ~ 400 nm excitation light (Chen, 2018; Luo et al., 2017; Sanketh et al., 2016).

Oral candidiasis (OC) is a superficial infection of fungi in the oral cavity that is common in patients with diabetes, xerostomia and acquired immune deficiency syndrome (AIDS); in patients on immunosuppressants or antibiotics; and those who have poor oral hygiene or are denture wearers (Berberi, Noujeim, & Aoun, 2015; Ellepola & Samaranayake, 2000; Lamster, Lalla, Borgnakke, & Taylor, 2008; Shinozaki et al., 2012; Soysa, Samaranayake, & Ellepola, 2008). Clinically, by tradition, OC is typically classified into erythematous candidiasis (acute and chronic), pseudomembranous candidiasis and chronic hyperplastic candidiasis (Lehner, 1967). In 1990, Samaranayake et al. updated the classification of OC as erythematous candidiasis (acute and chronic), pseudomembranous candidiasis (acute and chronic), hyperplastic candidiasis and candida-associated lesions (denture stomatitis, angular cheilitis and median rhomboid glossitis) (Samaranayake, Yaacoub, Samaranayake, & MacFarlane, 1990; Scully, Eikabir, & Samaranayake, 1994). Owing to the diversity of manifestations, differential diagnosis of OC among a variety of diseases is challenging. Therefore, a mycological technique is essential for definitive diagnosis.

Currently, 10% potassium hydroxide (KOH) smear and saliva culture are commonly applied in the clinic (Coronado-Castellote & Jimenez-Soriano, 2013). Although routinely performed, 10% KOH smear has rather low sensitivity and specificity. The sensitivity and specificity of 10% KOH smear in the diagnosis of OC have been reported to be 9.67% ~ 73.3% and 36.6% ~ 48.6%, respectively (Levitt, Levitt, Akhavan, & Yanofsky, 2010; Lyu, Zhao, Yan, & Hua, 2016; Marty, Bourrat, Vaysse, Bonner, & Bailleul-Forestier, 2015; Yue, Wang, Wang, Li, & Yue, 2018). Furthermore, other smear methods, such as Gram staining and periodic acid-Schiff (PAS) staining, are not suitable for clinical rapid diagnosis due to complicated and long time-consuming operation (Lyu et al., 2016; Yao, Shi, Zhang, Sun, & Wu, 2019). The culture technique has high sensitivity and specificity but is unable to distinguish infectious status from carrier status, and the long time required for culture leads to delayed diagnosis or misdiagnosis and increases the number of visits and the costs required of patients (Byadarahally & Rajappa, 2011; Williams & Lewis, 2000).

Hence, exploring a rapid and effective diagnostic technique with enhanced accuracy for the diagnosis of OC is worthwhile from both the clinical and economic perspective. To date, there is one study reported that CFW can be used in diagnosis of OC comparing with culture in oral swabs and PAS in oral biopsy tissues (Yao et al., 2019), and *Candida* detection using CFW was found to be higher than detection via PAS staining and Gram staining in cytopathology and histopathology of oral cancer and precancer (Bhavasar et al., 2010; Lynch & Gibson, 1987; Olsen & Stenderup, 1990). However, with respect to fluorescein-labelled chitinase in diagnosis of OC, there is a lack of evidence regarding the clinical application. Thus, this study was designed to evaluate the usefulness and accuracy of fluorescence staining for rapid diagnosis of OC, thereby providing research evidence for exploring approaches for rapid, effective and accurate diagnosis of OC.

2 | MATERIALS AND METHODS

2.1 | Study design

This study aimed to evaluate the diagnostic efficacy of fluorescence staining for rapid diagnosis of OC. The study followed the STARD statement (Bossuyt et al., 2015, 2003). The sample size was calculated as 124 in total, with 62 in each group. A 10% KOH smear and fluorescence staining of oral lesions were performed on all suspected OC subjects. All suspected OC patients were sequentially enrolled and ultimately allocated into either the OC group or the non-OC group based on the gold standard of diagnosis (combination of clinical manifestations, laboratory results and expert opinion). The study flow chart is summarized in Figure S1.

2.2 | Ethics

This study was approved by the Human Research Ethics Committee of Peking University Health Center (PKUSSIRB-201734024). All subjects signed a written informed consent before participation.

2.3 | Subjects

The subjects were outpatients of Peking University School and Hospital of Stomatology. The inclusion criteria were as follows: (a) 18 years and older, gender was not limited and (b) suspected OC. The exclusion criteria were as follows: (a) use of systemic anti-fungal agents and antibiotics within 1 month prior to participation or use of topical anti-fungal agents within 2 weeks prior to participation and (b) uncooperative patients for a psychological history or other disorders.

2.4 | Gold standard

The diagnosis of each subject was confirmed according to the clinical symptoms and signs, and whole saliva or oral rinse culture results, along with the opinion of two senior experts (Yan ZM and Hua H), were set as the gold standard for OC diagnosis (Coronado-Castellote & Jimenez-Soriano, 2013). In addition, histopathological examination was required for diagnosis of chronic hyperplastic candidiasis (Coronado-Castellote & Jimenez-Soriano, 2013). The classification of OC reported by Lehner in 1967 was used in this study (Lehner, 1967).

2.5 | Oral specimen collection, processing and interpretation

Samples for exfoliative cytology were obtained by scraping the suspected lesions. The exfoliated cells were smeared onto slides, stained by the addition of a fluorescent dye (Jiangsu Lifetime

Biological Technology Co. Ltd) and observed under a fluorescence microscope (OLYMPUS BX51, 340 ~ 400 nm, Japan); in addition, all samples were subjected to a routine 10% KOH smear test. Fluorescein-labelled chitinase can specifically bind to chitin in the cell wall of fungi, and the fungi then emit bright blue/green fluorescence (Chen, 2018; Luo et al., 2017; Sanketh et al., 2016). The smear results were recorded as positive if the hyphae exhibiting blue/green fluorescence were captured. Two researchers (Hu LJ and Zhou PR) read and recorded the results independently ($\kappa = 0.854$).

For culture, 1 ml unstimulated saliva or 5 ml oral rinse for patients with dry mouth was collected from each subject (Samaranayake, MacFarlane, Lamey, & Ferguson, 1986). Then, a 0.5 ml sample was incubated at 37°C for 48 hr on Sabouraud Dextrose Agar (BioMérieux) and CHROMagar plates (CHROMagar) to conduct qualitative and quantitative detection of *Candida* strains (Scully et al., 1994).

2.6 | Statistical analysis

SPSS 22.0 software (SPSS Inc.) was utilized to perform statistical analysis. The differences in age and sex between the two groups were analysed using a *t* test and chi-squared test. The diagnostic efficacy indexes (sensitivity, specificity, Youden index, predictive value, likelihood ratio, diagnostic odds ratio and diagnostic accuracy) and the value of Kappa reflecting the consistency of the microscopic examination results between the two examiners (Hu LJ and Zhou PR) were calculated. In addition, a receiver operator characteristic curve (ROC) was drawn and then obtained the area under the curve (AUC).

3 | RESULTS

3.1 | Baseline characteristics

In total, 124 subjects participated in the study, including 62 patients in the OC group and 62 in the non-OC group. No significant differences were found between the OC group and the non-OC group

with regard to age (61.26 ± 9.93 vs. 57.74 ± 11.59 , $p = .072$) and gender (Male/Female, 15/47 vs. 20/42, $p = .318$).

3.2 | Oral candidiasis types

In the OC group, the majority of subjects had erythematous candidiasis (59/62, 95.16%), and the rest had pseudomembranous candidiasis (2/62, 3.23%) or chronic hyperplastic candidiasis (1/62, 1.61%) (Table 1). The clinical manifestations of different OC types and the appearance of the fungal hyphae observed under a microscope are shown in Figure 1.

3.3 | Diagnostic efficacy

Among the 62 subjects in the OC group, 40 were positive in the 10% KOH smear, and 53 were positive in fluorescence staining; among the 62 subjects in the non-OC group, 45 were negative in the 10% KOH smear and 57 were negative in the fluorescence staining (Table 1). Therefore, both the sensitivity (85.48% vs. 64.52%, $p = .002$) and specificity (91.94% vs. 72.58%, $p = .004$) of fluorescence staining were significantly higher than those of the KOH smear. Furthermore, from the perspective of the Youden index, likelihood ratio, predictive value, diagnostic odds ratio and diagnostic accuracy, the diagnostic efficacy of fluorescence staining was also higher than that of the 10% KOH smear (Table 2).

Taking into account of the clinical types of OC, in erythematous candidiasis, the sensitivity of fluorescence staining was higher than that of the 10% KOH smear (84.75% vs. 62.71%, $p = .007$), suggesting that fluorescence staining is superior to 10% KOH smear, especially in diagnosis of erythematous type OC.

In addition, the ROC curves of the 10% KOH smear and fluorescence staining are shown in Figure 2, and the ROC curve of the fluorescence staining is close to the upper left corner of the coordinate system. The AUC of the fluorescence staining (0.887) was larger than that of the 10% KOH smear (0.685), revealing that the diagnostic efficacy of fluorescence staining was significantly higher than that of a routine 10% KOH smear ($p = .0005$).

TABLE 1 10% KOH smear and fluorescence staining results of all subjects

		KOH		Fluorescence	
		Positive (n)	Negative (n)	Positive (n)	Negative (n)
OC group (n = 62)	Erythematous candidiasis (n = 59)	37	22	50	9
	Pseudomembranous candidiasis (n = 2)	2	0	2	0
	Chronic hyperplastic candidiasis (n = 1)	1	0	1	0
Non-OC group (n = 62)		17	45	5	57
Total (n)		57	67	58	66

Abbreviation: KOH, potassium hydroxide; OC, oral candidiasis.

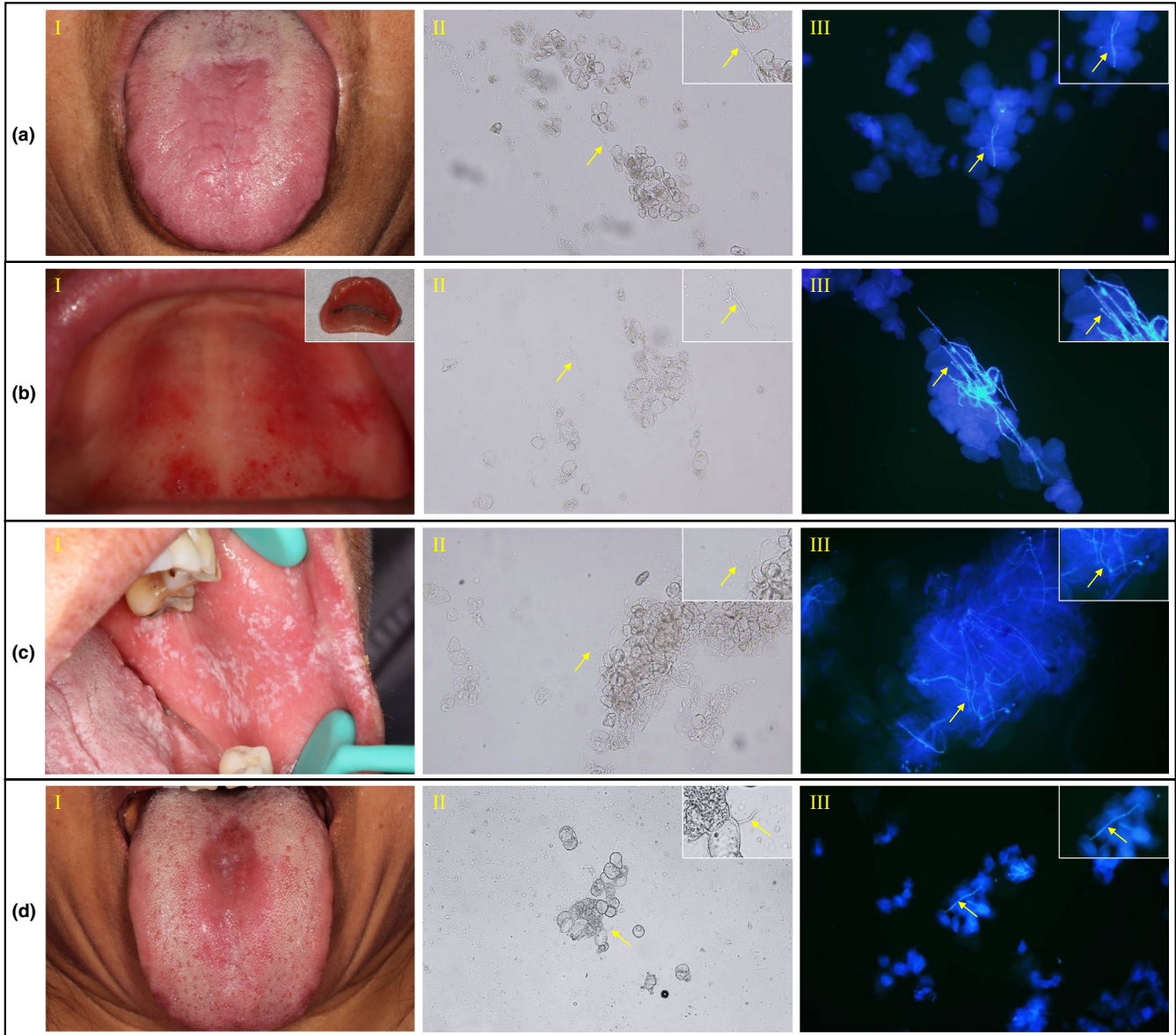


FIGURE 1 The positive result under the microscope ($\times 200$) (the top right images were the enlarged view of the fungal hyphae indicated by the yellow arrows). (a) Erythematous candidiasis. (b) Denture stomatitis, a typical candida-associated lesions due to wearing denture. (c) Pseudomembranous candidiasis. (d) Chronic hyperplastic candidiasis. I (clinical manifestation), II (10% KOH smear) and III (fluorescence staining) were the presentation of each type of oral candidiasis (OC) [Colour figure can be viewed at wileyonlinelibrary.com]

4 | DISCUSSION

Oral candidiasis is the most common opportunistic infection in the mouth and is due to *Candida* infection (Scully et al., 1994). *Candida* is an opportunistic pathogen (Matsubara, Bandara, Mayer, & Samaranyake, 2016; Ohshima, Ikawa, Kitano, & Maeda, 2018) that can be detected in the mouth of 30% ~ 55% of healthy adults and 45% ~ 65% of healthy infants (Arendorf & Walker, 1980; Samaranyake, 2009). In healthy carriers, *Candida* is an oval-shaped and rounded yeast and as a common commensal organism will not cause disease. However, when the symbiosis balance is disrupted, *Candida* multiplies locally and converts from a spore to a hypha, resulting in oral *Candida* infection (Coronado-Castellote &

Jimenez-Soriano, 2013). To date, the mainstay definitive diagnosis is based on clinical manifestations and is confirmed by mycological testing that primarily focuses on discovering the hyphae (Bilhan et al., 2009; Coronado-Castellote & Jimenez-Soriano, 2013; Lehner, 1967).

At present, 10% KOH smear is the most commonly used rapid and convenient diagnostic method. This technique has the advantages of ease of operation and low expense and could promptly distinguish hyphae and spores under a microscope. However, there is no colour difference between hyphae and cells. In addition, in the procedure, when exfoliated cells or food residue is over abundant in the smear, the hyphae/spores are not conspicuous under a microscope. Meanwhile, reading and interpretation of the results rely to some extent on the observer's experience, which may lead to missed

TABLE 2 The diagnostic efficacy calculation results of 10% KOH smear and fluorescence staining

	Sensitivity (%)		Specificity (%)		Youden index	PLR		NLR		PPV (%)		NPV (%)		Diagnostic accuracy (%)
	Point value	95% CI	Point value	95% CI		Point value	95% CI	Point value	95% CI	Point value	95% CI	Point value	95% CI	
KOH	64.52	51.27–75.96	72.58	59.56–82.78	0.37	2.35	1.51–3.67	0.49	0.35–0.69	70.18	56.43–81.20	67.16	54.49–77.85	68.55
Fluorescence	85.48	73.72–92.75	91.94	81.45–96.99	0.77	10.60	4.55–24.72	0.16	0.09–0.29	91.38	80.28–96.78	86.36	75.19–93.20	88.71

Abbreviations: KOH, potassium hydroxide; NLR, negative likelihood ratio; NPV, negative predictive value; PLR, positive likelihood ratio; PPV, positive predictive value.

diagnosis and misdiagnosis (Luo et al., 2017). Therefore, the rationale of this study was to explore a laboratory test that can facilitate rapid, effective and accurate diagnosis of OC in clinical practice.

In the well-designed diagnostic test presented here, we evaluated the potential of staining with fluorescein-labelled chitinase for rapid diagnosis of OC. Fluorescein-labelled chitinase is different from CFW because it specifically binds to chitin in the fungal cell wall, and the bond is more stable and tighter than non-specific binding (Luo et al., 2017; Roncero et al., 1988). Theoretically, this may lead to the high sensitivity and specificity of fluorescence staining using fluorescein-labelled chitinase (Han, Liu, Zhu, Li, & Zhang, 2016). Through clinical verification, this study found that the diagnostic efficacy of fluorescence staining was significantly higher than that of 10% KOH smear, and the AUC of fluorescence staining (0.887) was larger than that of the 10% KOH smear (0.685). It is generally considered that there is no diagnostic value when the AUC is below 0.5, the 0.5 ~ 0.7 AUC represents low accuracy, and the accuracy is high when the AUC is 0.7 ~ 0.9 (Chen, Ni, Pan, Liu, & Xia, 2005; Swets, 1988). Thus, the results suggest a high diagnostic value of fluorescence staining compared with the low diagnostic value of KOH.

Among the different subtypes of OC, erythematous candidiasis is the predominant type (95.16%), which is consistent with the reality in practice (Hu et al., 2019). Erythematous candidiasis is not only the most common type in the clinic but also more challenging to differentially diagnose compared with the pseudomembranous and hyperplastic types of candidiasis. It must be differentiated from a variety of diseases, including anaemia stomatitis, contact stomatitis, atrophic lichen planus and others, due to its diverse clinical manifestations. Therefore, accurate diagnosis of erythematous type candidiasis is of particular importance. In diagnosis of erythematous candidiasis, 42.5% of microscopic examinations were judged as yield false-negative results (Terai & Shimahara, 2009). It is reported that 10% KOH smear, although commonly used as a rapid and simple

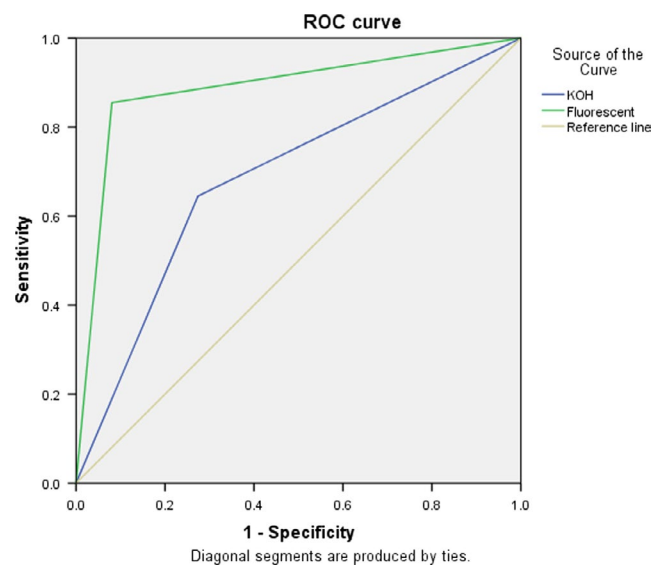


FIGURE 2 The receiver operator characteristic curve of 10% KOH smear and fluorescence staining [Colour figure can be viewed at wileyonlinelibrary.com]

diagnostic method, might miss a diagnosis or lead to misdiagnosis of erythematous candidiasis because the examiner has not scraped a sufficient number of exfoliated cells, and the number of hyphae is small when the infection is relatively mild, or saliva and food debris in the microscope field of view interfere with the assessment (Lyu et al., 2016; Sitheeque & Samaranyake, 2003). This study found that the positive rate of fluorescence staining in erythematous candidiasis was significantly higher than that of 10% KOH smear (84.75% vs. 62.71%, $p = .007$), revealing an advantage of fluorescence staining, especially in diagnosis of erythematous candidiasis.

Regarding the procedure, it is worth pointing out that, the average time required for the entire fluorescence staining process was approximately 5 min, which was a little shorter than or similar to that of 10% KOH smear, due to reducing the difficulties in the sample processing procedure as well as the difficulties in reading and interpreting the results. More importantly, fluorescence staining reduced the difficulties in the sample processing procedure as well as the difficulties in reading and interpreting the results. Owing to the short time in which the results can be read, the number of patient visits and the social-economic burden were reduced. In short, fluorescence staining has multiple advantages, such as ease of operation, high sensitivity and specificity, obvious contrast with the background under a fluorescence microscope and a shortened time of diagnosis, suggesting its potential for diagnosis of fungal infections in clinical settings (Sanketh et al., 2016).

Objectively, fluorescence staining also has some limitations. First, it should be noted that sample collection and processing could have an impact on the results assessed under a microscope, and necessary training is recommended. Second, a fluorescence microscope is required for this technique. Third, fluorescence staining cannot identify *Candida* strains, and thus, culture may be necessary as a supplement in some cases.

To summarize, fluorescence staining acts as a rapid and efficient diagnostic tool and has application potential for rapid diagnosis of oral candidiasis.

5 | CONCLUSION

Compared with routine 10% KOH smear, fluorescence staining with fluorescein-labelled chitinase significantly enhanced the accuracy of oral candidiasis diagnosis. The advantages of fluorescence staining in rapid diagnosis of oral candidiasis and its ease of operation suggest its potential in clinical practice.

ACKNOWLEDGEMENTS

The authors would like to thank all the participants for their cooperation and availability. This work was supported by the Program for New Clinical Techniques and Therapies of Peking University School and Hospital of Stomatology (PKUSSNCT-17A02) and the Natural Science Foundation of China (grant number 81570985). We would like to thank American Journal Experts for the assistance in language editing.

CONFLICTS OF INTEREST

The authors declare that they have no competing interests.

AUTHOR CONTRIBUTION

Yan ZM designed the study. Hu LJ, Zhou PR and Zhao WW conducted research. Yan ZM and Hua H conducted the diagnosis. Hu LJ and Yan ZM analysed data. Hu LJ drafted paper. Yan ZM revised the manuscript and final approved of the version to be submitted.

ORCID

Lijun Hu  <https://orcid.org/0000-0001-5196-5759>

Zhimin Yan  <https://orcid.org/0000-0002-0751-7374>

REFERENCES

- Arendorf, T. M., & Walker, D. M. (1980). The prevalence and intra-oral distribution of *Candida albicans* in man. *Archives of Oral Biology*, 25, 1–10. [https://doi.org/10.1016/0003-9969\(80\)90147-8](https://doi.org/10.1016/0003-9969(80)90147-8)
- Berberi, A., Noujeim, Z., & Aoun, G. (2015). Epidemiology of oropharyngeal Candidiasis in human immunodeficiency virus/acquired immune deficiency syndrome patients and CD4⁺ counts. *Journal of International Oral Health*, 7, 20–23.
- Bhavsar, R. S., Goje, S. K., Takalkar, A. A., Ganvir, S. M., Hazarey, V. K., & Gosavi, S. R. (2010). Detection of *Candida* by calcofluor white. *Acta Cytologica*, 54, 679–684. <https://doi.org/10.1159/000325232>
- Bilhan, H., Sulun, T., Erkose, G., Kurt, H., Erturan, Z., Kutay, O., & Bilgin, T. (2009). The role of *Candida albicans* hyphae and *Lactobacillus* in denture-related stomatitis. *Clinical Oral Investigation*, 13, 363–368. <https://doi.org/10.1007/s00784-008-0240-6>
- Bossuyt, P. M., Reitsma, J. B., Bruns, D. E., Gatsonis, C. A., Glasziou, P. P., Irwig, L. M., ... de Vet, H. C. (2003). Towards complete and accurate reporting of studies of diagnostic accuracy: The STARD initiative. *BMJ*, 326, 41–44. <https://doi.org/10.1136/bmj.326.7379.41>
- Bossuyt, P. M., Reitsma, J. B., Bruns, D. E., Gatsonis, C. A., Glasziou, P. P., Irwig, L., ... Cohen, J. F. (2015). STARD 2015: An updated list of essential items for reporting diagnostic accuracy studies. *BMJ*, 351, h5527.
- Byadarahally, R. S., & Rajappa, S. (2011). Isolation and identification of *Candida* from the oral cavity. *ISRN Dentistry*, 2011, 487921. <https://doi.org/10.5402/2011/487921>
- Chen, H. (2018). Comparison of fluorescence staining and KOH wet film in the diagnosis of superficial fungal infections. *China Health Standard Management*, 9, 108–109. (In Chinese).
- Chen, R. J., Tong, T., Li, C., Wu, X., Chen, Q., Chen, X. N., ... Chen, B. R. (2016). Comparison of fluorescent staining method and KOH wet method for diagnosis of superficial fungal infections. *Chinese Journal of Mycology*, 11, 378–380. (In Chinese).
- Chen, W. Z., Ni, Z. Z., Pan, X. P., Liu, Y. Y., & Xia, Y. (2005). Receiver operating characteristic curves to determine the optimal operating point and doubttable value interval. *Modern Preventive Medicine*, 32, 729–731. (In Chinese).
- Chick, E. W., & Behar, V. S. (1961). A simple fluorescent method for the detection of superficial fungi in skin and hair. A combined stain with acridine orange and potassium hydroxide. *The Journal of Investigative Dermatology*, 37, 103–105. <https://doi.org/10.1038/jid.1961.90>
- Coronado-Castellote, L., & Jimenez-Soriano, Y. (2013). Clinical and microbiological diagnosis of oral candidiasis. *Journal of Clinical and Experimental Dentistry*, 5, e279–e286. <https://doi.org/10.4317/jced.51242>
- Ellepola, A. N., & Samaranyake, L. P. (2000). Oral candidal infections and antimycotics. *Critical Reviews in Oral Biology and Medicine*, 11, 172–198. <https://doi.org/10.1177/10454411000110020301>



- Han, D. M., Liu, Y. Z., Zhu, J. H., Li, L., & Zhang, Q. Q. (2016). Comparison of novel fluorescent staining and KOH microscopic examination in fungal measured by direct microscopy. *Chinese Journal of Mycology*, 11, 240–242. (In Chinese).
- He, W. J., Gao, Z. Q., Chen, J., Ren, H. J., Yang, H., Cai, Q., & Yang, L. J. (2018). CFW fluorescent staining in detecting suspected fungal infection. *Laboratory Medicine*, 33, 331–334. (In Chinese).
- Higareda-Almaraz, M. A., Loza-Barajas, H., Maldonado-Gonzalez, J. G., Higareda-Almaraz, E., Benitez-Godinez, V., & Murillo-Zamora, E. (2016). Usefulness of direct fluorescent in buffy coat in the diagnosis of Candida sepsis in neonates. *Journal of Perinatology*, 36, 874–877.
- Hu, L., He, C., Zhao, C., Chen, X., Hua, H., & Yan, Z. (2019). Characterization of oral candidiasis and the Candida species profile in patients with oral mucosal diseases. *Microbial Pathogenesis*, 134, 103575.
- Lamster, I. B., Lalla, E., Borgnakke, W. S., & Taylor, G. W. (2008). The relationship between oral health and diabetes mellitus. *Journal of the American Dental Association*, 139(Suppl), 19S–24S.
- Lehner, T. (1967). Oral Candidosis. *Dental Practitioner and Dental Record*, 17, 209–216.
- Levitt, J. O., Levitt, B. H., Akhavan, A., & Yanofsky, H. (2010). The sensitivity and specificity of potassium hydroxide smear and fungal culture relative to clinical assessment in the evaluation of tinea pedis: A pooled analysis. *Dermatology Research and Practice*, 2010, 764843.
- Luo, Y. P., Gao, Y. M., Jin, Y., Jiang, Q., Li, J., Fan, X. Y., & Zhan, P. (2017). Fluorescent staining with hypersensitivity and enhancement for early diagnosis of superficial fungal infection. *Chinese Journal of Clinical Laboratory Science*, 35, 736–738. (In Chinese).
- Lynch, D. P., & Gibson, D. K. (1987). The use of Calcofluor white in the histopathologic diagnosis of oral candidiasis. *Oral Surgery, Oral Medicine, Oral Pathology*, 63, 698–703. [https://doi.org/10.1016/0030-4220\(87\)90373-2](https://doi.org/10.1016/0030-4220(87)90373-2)
- Lyu, X., Zhao, C., Yan, Z. M., & Hua, H. (2016). Accuracy of three methods for the rapid diagnosis of oral candidiasis. *Zhonghua Kou Qiang Yi Xue Za Zhi*, 51, 610–615.
- Marty, M., Bourrat, E., Vaysse, F., Bonner, M., & Bailleul-Forestier, I. (2015). Direct microscopy: A useful tool to diagnose oral candidiasis in children and adolescents. *Mycopathologia*, 180, 373–377.
- Matsubara, V. H., Bandara, H. M., Mayer, M. P., & Samaranayake, L. P. (2016). Probiotics as antifungals in mucosal candidiasis. *Clinical Infectious Diseases*, 62, 1143–1153.
- Moussa, S. H., Tayel, A. A., & Al-Turki, A. I. (2013). Evaluation of fungal chitosan as a biocontrol and antibacterial agent using fluorescence-labeling. *International Journal of Biological Macromolecules*, 54, 204–208.
- Ohshima, T., Ikawa, S., Kitano, K., & Maeda, N. (2018). A proposal of remedies for oral diseases caused by Candida: A mini review. *Frontiers in Microbiology*, 9, 1522.
- Olsen, I., & Stenderup, A. (1990). Clinical-mycologic diagnosis of oral yeast infections. *Acta Odontologica Scandinavica*, 48, 11–18.
- Roncero, C., & Duran, A. (1985). Effect of Calcofluor white and Congo red on fungal cell wall morphogenesis: In vivo activation of chitin polymerization. *Journal of Bacteriology*, 163, 1180–1185.
- Roncero, C., Valdivieso, M. H., Ribas, J. C., & Duran, A. (1988). Effect of calcofluor white on chitin synthases from *Saccharomyces cerevisiae*. *Journal of Bacteriology*, 170, 1945–1949.
- Samaranayake, L. P. (2009). Commensal oral Candida in Asian cohorts. *International Journal of Oral Science*, 1, 2–5.
- Samaranayake, L. P., MacFarlane, T. W., Lamey, P. J., & Ferguson, M. M. (1986). A comparison of oral rinse and imprint sampling techniques for the detection of yeast, coliform and Staphylococcus aureus carriage in the oral cavity. *Journal of Oral Pathology*, 15, 386–388.
- Samaranayake, L. P., Yaacoub, H. B., Samaranayake, L. P., & MacFarlane, T. W. (1990). Classification of Oral Candidosis. *Oral Candidosis*, 1990, 124–132.
- Sanketh, D. S., Patil, S., & Rao, R. S. (2016). Estimating the frequency of Candida in oral squamous cell carcinoma using Calcofluor White fluorescent stain. *Journal of Investigative and Clinical Dentistry*, 7, 304–307.
- Scully, C., Eikabir, M., & Samaranayake, L. P. (1994). Candida and oral candidosis: A review. *Critical Reviews in Oral Biology and Medicine*, 5, 125–157.
- Shinozaki, S., Moriyama, M., Hayashida, J. N., Tanaka, A., Maehara, T., Ieda, S., & Nakamura, S. (2012). Close association between oral Candida species and oral mucosal disorders in patients with xerostomia. *Oral Diseases*, 18, 667–672.
- Sitheequ, M. A., & Samaranayake, L. P. (2003). Chronic hyperplastic candidosis/candidiasis (candidal leukoplakia). *Critical Reviews in Oral Biology and Medicine*, 14, 253–267.
- Soyas, N. S., Samaranayake, L. P., & Ellepola, A. N. (2008). Antimicrobials as a contributory factor in oral candidosis—A brief overview. *Oral Diseases*, 14, 138–143.
- Swets, J. A. (1988). Measuring the accuracy of diagnostic systems. *Science*, 240, 1285–1293.
- Terai, H., & Shimahara, M. (2009). Usefulness of culture test and direct examination for the diagnosis of oral atrophic candidiasis. *International Journal of Dermatology*, 48, 371–373.
- Williams, D. W., & Lewis, M. A. (2000). Isolation and identification of Candida from the oral cavity. *Oral Diseases*, 6, 3–11.
- Yao, Y., Shi, L., Zhang, C., Sun, H., & Wu, L. (2019). Application of fungal fluorescent staining in oral candidiasis: Diagnostic analysis of 228 specimens. *BMC Microbiology*, 19, 96.
- Yue, X., Wang, A., Wang, H., Li, Q., & Yue, X. (2018). Evaluation of a new fluorescent reagent, fluorescent brightener 85, for the diagnosis of suspected onychomycosis compared with potassium hydroxide. *Mycoses*, 61, 279–282.

SUPPORTING INFORMATION

Additional supporting information may be found online in the Supporting Information section.

How to cite this article: Hu L, Zhou P, Zhao W, Hua H, Yan Z. Fluorescence staining vs. routine KOH smear for rapid diagnosis of oral candidiasis—A diagnostic test. *Oral Dis*. 2020;26:941–947. <https://doi.org/10.1111/odi.13293>