

# Intraosseous Venous Malformations of the Zygoma: Report of 4 Cases and Literature Review

Annals of Otolaryngology & Laryngology  
1–5  
© The Author(s) 2017  
Reprints and permissions:  
sagepub.com/journalsPermissions.nav  
DOI: 10.1177/0003489417701934  
journals.sagepub.com/home/aor  


Xiuling Huang, DDS<sup>1</sup>, Jingang An, DDS, MD<sup>1</sup>, Yi Zhang, DDS, MD, PhD<sup>1</sup>, and Zhigang Cai, DDS, MD, PhD<sup>1</sup>

## Abstract

**Objectives:** As intraosseous venous malformations (IVMs) of the zygoma are very rare and clinical features are not typical, a correct preoperative diagnosis may be difficult to make. This study presents 4 cases of IVM of the zygoma and gives a review of their clinical manifestations, radiographic features, preoperative diagnosis, and differentials.

**Methods:** The report of 4 cases was performed with an average 6-year follow-up. Medical records including clinical, radiographic, and histopathological information were reviewed.

**Results:** All the patients were mid-aged women with a complaint of an enlarging mass over the midface. They all failed to receive a definite preoperative diagnosis, and the diagnoses of IVM in all patients were made via pathological evidence. Although they received different surgical treatments, all the follow-up results (2~12 years) were satisfactory.

**Conclusion:** Intraosseous venous malformations of the zygoma are benign lesions caused by abnormal vessel morphogenesis. Patients usually present in their 40s with a tender or painless swelling of the zygoma. The key to the diagnosis is the typical sunburst pattern of radiating trabeculae with intact cortices on computed tomographic scans. Intraosseous venous malformations should be differentiated from other lesions, including intraosseous meningioma, fibrous dysplasia, osteochondroma, osteosarcoma, and ossifying fibroma.

## Keywords

zygoma, intraosseous venous malformation, preoperative diagnosis, differential diagnosis, treatment

## Introduction

Intraosseous vascular malformations represent about 0.5% to 1% of all bony neoplastic and tumor-like lesions.<sup>1</sup> Involvement of the maxillofacial skeleton is uncommon, with the mandible and maxilla most frequently involved.<sup>2</sup> Zygomatic involvement is extremely rare, with only 38 cases reported in the English literature to date.<sup>3</sup> According to the significant and valuable classification introduced by Mulliken and Glowacki<sup>4</sup> in 1982, all of the 38 cases were actually more appropriately termed as *intraosseous venous malformations*<sup>5</sup> (IVMs) instead of other vascular malformations.

We present 4 cases of IVM of the zygoma all without definite preoperative diagnoses. We review their clinical manifestations, radiographic features, and especially preoperative diagnosis and differentials.

## Case Report

### Case No. 1

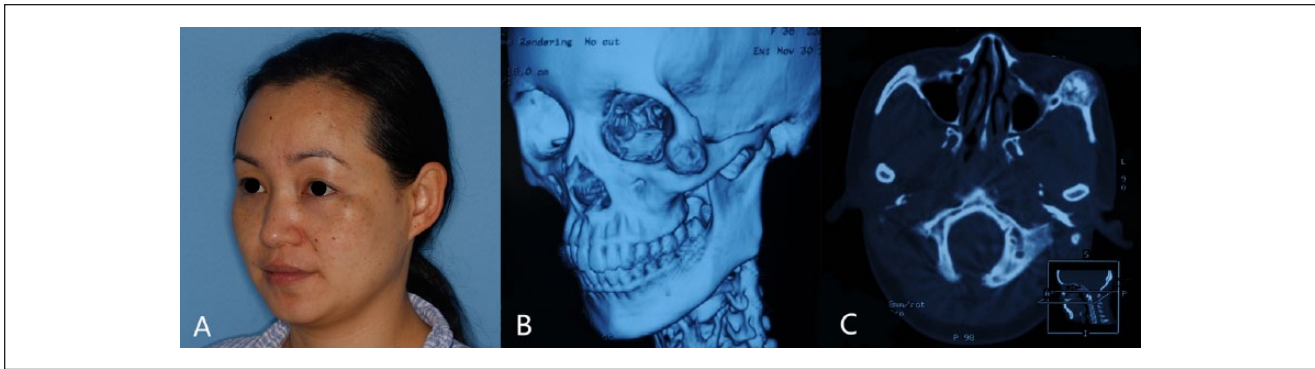
A 35-year-old woman presented with a 7-year history of an enlarging mass over the left zygoma. The patient

accidentally perceived the left malar enlargement without any discomfort and received no treatment. After childbirth, the patient began to experience spontaneous hemifacial pain, and the growth of mass was accelerated. She denied other symptoms such as difficulties in eyeball movement and diplopia. Clinical examination revealed a 2.5 × 2.5 × 2.0 cm well-defined hard immobile mass over the left zygoma with mild tenderness on palpation. The superficial skin was normal, and the mass was not fixed to the skin (Figure 1A). A computed tomographic (CT) scan of the head revealed a well-defined round mass protruding from the body of the left zygoma, showing a sunburst pattern of radiating trabeculae with intact cortices (Figures 1B, 1C). The patient underwent complete excision with free iliac

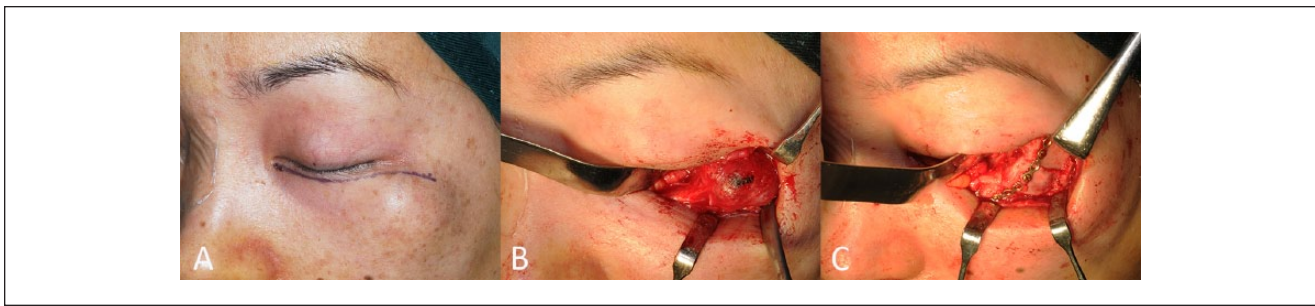
<sup>1</sup>Department of Oral and Maxillofacial Surgery, Peking University School and Hospital of Stomatology, Beijing, P.R. China

### Corresponding Author:

Jingang An, MD, Department of Oral and Maxillofacial Surgery, Peking University School and Hospital of Stomatology, 22 Zhongguancun Nandajie, Haidian District, Beijing, 100081, P.R. China.  
Email: anjingang@126.com



**Figure 1.** Preoperative appearance and computed tomographic (CT) imaging of the head. (A) Preoperative appearance. The left malar mass bulged outward. (B) Three-dimensional CT. The round bony mass was located in the left zygoma body, bulging outward. (C) Axial CT image. There was some scattered high density inside, and the arrangement of trabeculae was radiated. The marginal cortices were clear and intact.



**Figure 2.** Intraoperative view. (A) Mark of the left lower eyelid incision. (B) The incision was opened, and the bony mass over the left zygoma was fully exposed. (C) After complete excision, the left iliac bone graft of  $2.5 \times 2.5 \times 2.0$  cm was filled in the bony defect and was fixed by a mini titanium plate.

bone graft reconstruction under general anesthesia. The mass was exposed through a left lower eyelid incision. It was round and fuchsia-colored, bled easily, and had a honeycombed internal structure. After complete excision, a left iliac bone graft of  $2.5 \times 2.5 \times 2.0$  cm was collected to fill in the bony defect. The orbital floor defect was filled by the cortical side of graft, and the graft was fixed with a mini titanium plate (Figure 2). The intraoperative blood loss was about 50 ml. The pathological diagnosis was IVM. By 10 months after the surgery, symmetry of the midface was achieved without obvious scars (Figure 3A). Postoperative CT scan showed that the left zygomatic area was superficially smooth without signs of recurrence (Figures 3B, 3C). As the patient requested, the titanium plate and screws were removed. The follow-up results to date (3 years) have shown no signs of recurrence.

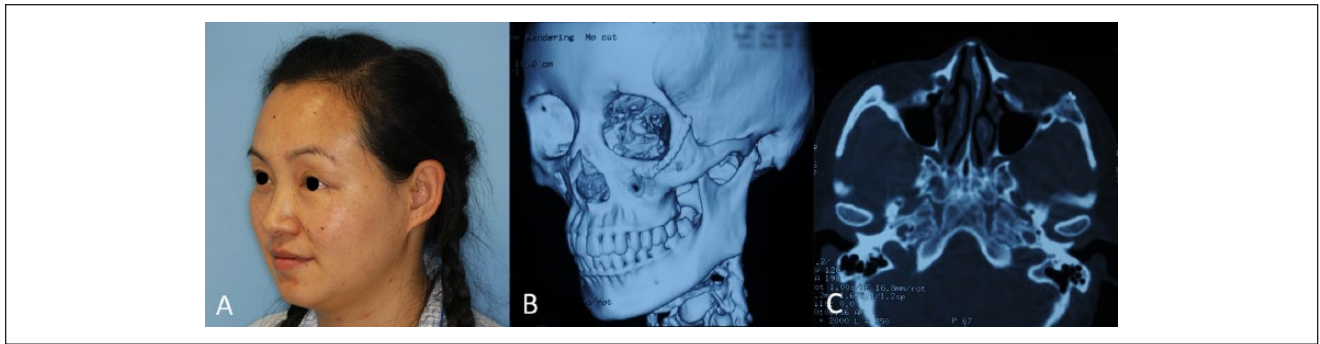
### Case No. 2

A 41-year-old woman presented with a 2-year history of a gradually enlarging mass along the left infralateral orbital rim. The patient accidentally detected an eminence without

discomfort, and there had been no significant growth of the mass over the past 2 years. The clinical examination revealed a 1.5 cm hemispherical enlargement below the left outer canthus. It was hard and immobile with tenderness on palpation. The temperature and color of the overlying skin were normal, as were the results of ophthalmological examinations. A CT scan demonstrated a mass over the left zygoma with a sunburst pattern of radiating trabeculae with intact cortices. The patient underwent partial resection under general anesthesia. The mass was exposed through a lower eyelid incision, and the outer bulging portion was resected. The intraoperative blood loss was 10 ml. The pathological diagnosis was IVM, and there was no evidence of increased growth at 2-year follow-up.

### Case No. 3

A 49-year-old woman presented with a 4-month history of a gradually enlarging mass over the right zygoma. The patient had no discomfort like pain or ophthalmological symptoms. Clinical examination revealed a 1 cm bony eminence over the right zygoma body. It was hard and immobile and was



**Figure 3.** Postoperative appearance and computed tomographic (CT) imaging of the head after 10 months. (A) Postoperative appearance. No abnormal enlargement was in the left zygomatic region. (B) Three-dimensional CT. The left zygomatic area was superficially smooth without signs of recurrence. (C) Axial CT image. The zygomatic symmetry was achieved.

not fixed to the skin. The preoperative CT scan (obtained from the case record) showed a round, well-defined radiolucency with trabecular density inside. Under general anesthesia, the patient underwent aggressive curettage of the mass, deep into the normal bone. The intraoperative blood loss was 10 ml. The pathological diagnosis was IVM, and the 7-year follow-up results showed no signs of recurrence.

#### Case No. 4

A 44-year-old woman presented with a 3-month history of a progressively enlarging mass over the left zygoma. At first, the mass was as big as a peanut and was asymptomatic. Then, it enlarged and eventually increased to the size of a walnut. The patient began to perceive ipsilateral eye discomfort. Physical examination revealed a 2 cm immobile hard mass with a nodular surface. Ophthalmological examination yielded normal results. The preoperative CT scan (obtained from the case record) showed a well-defined bony eminence. The mass was partially resected through a lower eyelid incision. The intraoperative blood loss was 30 ml. The pathological diagnosis was IVM, and the 12-year follow-up results showed no signs of increased growth.

## Discussion

### *Pathogenesis and Biological Features*

Like other vascular malformations, IVMs are believed to be caused by errors in vascular morphogenesis during embryogenesis.<sup>6</sup> Unlike soft tissue lesions, IVMs are sequestered in the deep bone, so early symptoms are not obvious.<sup>1</sup> The growth of IVM is usually slow and synchronized with the growth and development of the body. Infection and trauma could trigger a growth spurt.<sup>7,8</sup> The lesion can expand throughout puberty and during pregnancy in female patients because they are responsive to estrogens.<sup>9</sup> In case No. 1, the growth of the mass was accelerated during pregnancy.

### *Clinical and Auxiliary Examinations*

Patients involved with IVMs of the zygoma usually present in their 40s, with a tender or painless swelling of the malar eminence. There appears to be a 3:1 female dominance, and the lesion more commonly occurs on the left.<sup>10</sup> Patients may have other symptoms like hemorrhage, cosmetic deformity, proptosis, and diplopia. The mass is often painless, although hemifacial pain has been reported.<sup>5</sup> The clinical results of reported cases were consistent with those reported previously.

Since clinical features are not specific, CT scans could be an effective diagnostic tool for zygomatic IVMs. A well-defined expansile lesion showing a sunburst pattern of radiating trabeculae with intact cortices is characteristic of IVMs on CT scans (Figure 1C).<sup>10</sup> The radiating sunburst pattern occurs because of the bony spicules oriented perpendicular to the mass border.<sup>11</sup> On the basis of the CT features of our cases, and with reference to others' experience,<sup>12</sup> we summarized the radiological characteristics of this disease as follows: (1) well-defined cystic radiolucent area with intact cortices and internal bony septations, (2) a honeycombed or sunburst appearance with spindles radiating toward the periphery, (3) bone trabeculae radiating from the center to the periphery of the lesion, (4) a variable number of phleboliths may be present, and (5) no obvious enhancement is found on contrast-enhanced CT scanning.

Magnetic resonance imaging (MRI) characterizes soft tissue lesion architecture but is limited for intraosseous lesion. In general, IVMs show hypointensity on T1WI and hyperintensity on T2WI.<sup>10</sup> However, other intraosseous cystic lesions, for example odontogenic cysts and ameloblastoma, also have similar MRI characteristics.

When a vasogenic lesion is suspected, routine biopsy is prohibited, though fine-needle aspiration biopsy could be considered. However, it is difficult to penetrate the bone surface and obtain useful tissues with this method.<sup>13</sup>

## Diagnosis and Differentials

Preoperative diagnosis of IVM is mainly based on radiological examination, especially CT scan. Its typical CT image is a well-defined expansile radiolucency with a sunburst pattern of radiating trabeculae. The differential diagnoses include intraosseous meningioma, fibrous dysplasia, osteochondroma, osteosarcoma, and ossifying fibroma. Intraosseous meningiomas show hyperostosis and have soft tissue components.<sup>14</sup> Fibrous dysplasia is usually ill defined and presents a typical ground-glass appearance, while the characteristic feature of osteochondroma is cortico-medullary continuity. Osteosarcomas can also show the sunburst pattern, but they are characteristic of cortical bone damage, periosteal reaction, and soft tissue reaction. The CT images of ossifying fibromas and IVMs are similar; however, the images of ossifying fibromas show inner scattered opacity without the sunburst pattern.

The available preoperative CT images of case Nos. 1 and 2 both showed the typical sunburst pattern, so preoperative diagnosis of IVM was supposed to be made. However, due to the very low incidence of the lesion and surgeons' insufficient experience, the definite diagnosis could not be made preoperatively. All the patients were eventually diagnosed as IVMs based on the pathological evidence. Their histopathological features are as follows: (1) interspersed mature bone trabeculae between thin-walled vascular spaces and (2) the central dilated vein is lined by flattened endothelium and lacks a uniform muscular layer.

## Treatment

Given the benign nature of IVMs, observation is considered adequate for asymptomatic patients. When patients present with facial deformity, hemorrhage, pain, or complications of mass effect, surgery is recommended. Our results show that as long as adequate hemostasis was ensured in surgery, the blood loss would be controlled. The surgical intervention is usually comprised of 3 techniques: complete resection, partial resection, and curettage. Most authors support complete resection,<sup>15,16</sup> which has been shown to lower recurrence rates.<sup>17</sup> Partial resection and curettage are less destructive and can avoid facial deformity, but intraoperative hemorrhage and recurrences have been reported.<sup>18</sup>

Among the patients in the present study, 1 underwent complete resection (3-year follow-up), 2 underwent partial resection (2-year and 12-year follow-up), and 1 underwent curettage (7-year follow-up). No recurrence or increased growth (for case Nos. 2 and 4) has been found to date in any of these patients.

## Conclusion

Since IVMs of the zygoma are rare and clinical features are not typical, it may be difficult for surgeons to make a

correct preoperative diagnosis. The key to their diagnosis is the typical sunburst pattern of radiating trabeculae with intact cortices on CT scans.

## Acknowledgments

We thank those patients who participated in the study.

## Declaration of Conflicting Interests

The author(s) declared no potential conflicts of interest with respect to the research, authorship, and/or publication of this article.

## Funding

The author(s) received no financial support for the research, authorship, and/or publication of this article.

## References

- Colletti G, Frigerio A, Giovanditto F, et al. Surgical treatment of vascular malformations of the facial bones. *J Oral Maxillofac Surg.* 2014;72(7):1321-1326.
- Vardas E, Stavrou E, Leventis M, et al. Intraosseous mandibular venous malformation. *J Craniofac Surg.* 2011;22(6):e44-e47.
- Defazio MV, Kassira W, Camison L, et al. Intraosseous venous malformations of the zygoma: clarification of misconceptions regarding diagnosis and management. *Ann Plast Surg.* 2014;72(3):323-327.
- Mulliken JB, Glowacki J. Hemangiomas and vascular malformations in infants and children: a classification based on endothelial characteristics. *Plast Reconstr Surg.* 1982;69(3):412-422.
- Srinivasan B, Ethunandan M, Van der Horst C, Markus AF. Intraosseous "haemangioma" of the zygoma: more appropriately termed a venous malformation. *Int J Oral Maxillofac Surg.* 2009;38(10):1066-1070.
- Colletti G, Valassina D, Bertossi D, et al. Contemporary management of vascular malformations. *J Oral Maxillofac Surg.* 2014;72(3):510-528.
- Sweet C, Silbergleit R, Mehta B. Primary intraosseous hemangioma of the orbit: CT and MR appearance. *AJNR Am J Neuroradiol.* 1997;18(2):379-381.
- Zucker JJ, Levine MR, Chu A. Primary intraosseous hemangioma of the orbit. Report of a case and review of literature. *Ophthal Plast Reconstr Surg.* 1989;5(4):247-255.
- Burns AJ, Navarro JA, Cooner RD. Classification of vascular anomalies and the comprehensive treatment of hemangiomas. *Plast Reconstr Surg.* 2009;124(1 suppl):e69-e81.
- Moore SL, Chun JK, Mitre SA, Som PM. Intraosseous hemangioma of the zygoma: CT and MR findings. *AJNR Am J Neuroradiol.* 2001;22(7):1383-1385.
- Charles NC, Lisman RD. Intraosseous hemangioma of the orbit. *Ophthalmic Surg Lasers.* 2002;33(4):326-328.
- Gomez OG, Garcia-Rozado A, Luaces RR. Intraosseous mandibular hemangioma. A case report and review of the literature. *Med Oral Patol Oral Cir Bucal.* 2008;13(8):E496-E498.
- Marcinow AM, Provenzano MJ, Gurgel RK, Chang KE. Primary intraosseous cavernous hemangioma of the zygoma:



- a case report and literature review. *Ear Nose Throat J.* 2012;91(5):210-214.
14. Tokgoz N, Oner YA, Kaymaz M, et al. Primary intraosseous meningioma: CT and MRI appearance. *AJNR Am J Neuroradiol.* 2005;26(8):2053-2056.
  15. Koybasi S, Saydam L, Kutluay L. Intraosseous hemangioma of the zygoma. *Am J Otolaryngol.* 2003;24(3):194-197.
  16. Sary A, Yavuzer R, Latfoglu O, Celebi MC. Intraosseous zygomatic hemangioma. *Ann Plast Surg.* 2001;46(6):659-660.
  17. Zins JE, Turegun MC, Hosn W, Bauer TW. Reconstruction of intraosseous hemangiomas of the midface using split calvarial bone grafts. *Plast Reconstr Surg.* 2006;117(3):948-953.
  18. Konior RJ, Kelley TF, Hemmer D. Intraosseous zygomatic hemangioma. *Otolaryngol Head Neck Surg.* 1999;121(1):122-125.