
The detection accuracies for proximal caries by cone-beam computerized tomography, film, and phosphor plates

Zhi-ling Zhang, DDS, Xing-min Qu, DDS, MSc, Gang Li, DDS, PhD,
Zu-yan Zhang, DDS, PhD, and Xu-chen Ma, DDS, PhD
DEPARTMENT OF ORAL AND MAXILLOFACIAL RADIOLOGY, PEKING UNIVERSITY SCHOOL AND
HOSPITAL OF STOMATOLOGY, BEIJING, CHINA

Objectives. To evaluate the accuracy of cone-beam computerized tomography (CBCT) for the detection of noncavitated proximal caries and to compare the detection accuracies of 2 CBCT imaging systems with those based on plain-film radiographs and phosphor-plate images.

Study design. Test radiographs of 39 noncavitated unrestored human permanent teeth were obtained with film, phosphor-plate, ProMax 3D, and Kodak 9000 3D imaging systems. Seven observers used a 5-level scale to evaluate test images for the presence of proximal caries. With histologic examination serving as the reference standard, observer performances were assessed with receiver operating characteristic (ROC) curves, and the areas under the ROC curves (A_z values) for the observers, and modalities were analyzed with a repeated-measures analysis of variance.

Results. The mean A_z values for film, phosphor plates, ProMax 3D, and Kodak 9000 3D imaging systems were 0.541, 0.523, 0.528, and 0.525, respectively ($P = .763$).

Conclusion. For detecting subtle noncavitated proximal caries, the detection accuracy with the CBCT images was little better than chance performance and was similar to that with phosphor plate- and film-based intraoral images. (**Oral Surg Oral Med Oral Pathol Oral Radiol Endod 2011;111:103-108**)

Dental clinicians currently rely primarily on visual inspection and intraoral radiography to diagnose caries.¹ Intraoral film radiography is an established and conventional method for caries diagnosis, especially for proximal caries that are hard to identify through direct inspection. Digital intraoral radiography, which was introduced in the early 1980s, is one alternative method.² The accuracy of caries detection with digital and film radiography is similar, and neither modality satisfactorily detects incipient proximal lesions.³⁻⁵ In one study, the areas under the receiver operating characteristic (ROC) curves for proximal enamel caries were 0.6565 and 0.6167 for film and digital radiography.⁴ A limitation of intraoral radiography is that it is a 2-dimensional (2D) imaging method that is used to record 3-dimensional (3D) anatomic structures.

Recent studies have focused on the dental application of 3D imaging modalities to avoid the overlap of 3D anatomic structures in 2D images.⁶⁻¹¹ Cone-beam computerized tomography (CBCT) uses a 2D x-ray detector and a cone- or pyramid-shaped x-ray beam to reconstruct isotropic high-spatial-resolution, 3D images from

which projection images can be made.¹² Advantages of CBCT imaging are its accessibility, ease of handling, and ability to offer (from a single scan) a dataset of multiplanar cross-sectional and 3D reconstructions.¹³

As CBCT has become more widely adopted, a provisional guideline for its application has been produced by the SEDENTEXCT project in Europe. Based on a systematic review of published studies in which early versions of CBCT were employed, these guidelines do not recommend CBCT for caries diagnosis.¹⁴ For the most recently developed CBCT imaging systems, such as the Kodak 9000 3D (Carestream Health, Rochester, NY, USA) and ProMax 3D (Planmeca, Helsinki, Finland), caries detection accuracy has not been determined.

The aims of the present study were to evaluate the accuracies of the ProMax 3D and Kodak 9000 3D imaging systems for the detection of noncavitated proximal caries and to compare the detection accuracies of the CBCT imaging systems with those based on Ektaspeed film and storage phosphor plates.

MATERIALS AND METHODS

Teeth

Thirty-nine noncavitated human permanent teeth were extracted from 11 excised jaws.¹⁵ The study plan was approved by the Ethical Committee of Peking University Health Science Center. The clinical appearances of the tooth surfaces ranged from sound to dis-

Received for publication Jan 8, 2010; returned for revision Jun 2, 2010; accepted for publication Jun 29, 2010.
1079-2104/\$ - see front matter
© 2011 Mosby, Inc. All rights reserved.
doi:10.1016/j.tripleo.2010.06.025

Table I. Specifications of different imaging systems when taking radiographs

	<i>kV</i>	<i>mA</i>	<i>Exposure time(s)</i>	<i>Detector</i>	<i>FOV (cm)</i>	<i>Voxel size (mm)</i>	<i>Slice thickness (mm)</i>
Film	60	7	0.25	E-speed	—	—	—
Digital	60	7	0.2	SPP	—	—	—
ProMax 3D	76	6	3.15	CMOS	8 × 8	0.32	0.32
Kodak 9000 3D	70	10	10.8	AFP	5 × 3.7	0.076	0.076

FOV, Field of view; *SPP*, storage phosphor plate; *CMOS*, complementary metal oxide semiconductor; *AFP*, amorphous silicon flat panel.

colored, with white/brown discolorations. The teeth were mounted in 11 plaster blocks, with the most prominent part of the proximal surfaces in contact and at the same vertical level to simulate the normal anatomic position.

Test radiographs

Radiographic images of the teeth were made using Kodak E-speed films (Carestream Health) and phosphor plates (Digora Optime digital imaging system; Soredex, Helsinki, Finland). The x-ray unit used was a Soredex MinRay with a focal spot size of 0.7 mm, 2-mm Al filtration, and a constant nominal tube potential selectable at either 60 kVcp or 70 kVcp. The radiographs of the teeth were obtained using a specially designed holder to provide a standardized projection geometry in the buccolingual direction. A 20-mm acrylic block was placed in front of the tooth block to produce a soft-tissue equivalent scattering effect. The exposure specifications for film, digital, and CBCT images are presented in Table I. Following the manufacturer's instructions, the film radiographs were developed in an automatic film processor (XR 25s; Dürr Dental, Bi-etingheim-Bissingen, Germany). All films were processed with fresh Dürr-Automat XR/C chemicals (Dürr Dental). The processed radiographs were mounted in nontransparent frames for later evaluation. Digital images were obtained after exposure by immediately scanning the phosphor plates with the proprietary Dfw v.2.5 software. The selected scanning resolution was 400 dpi. The raw data images were processed with the proprietary default processing algorithm and saved as 8-bit images.

CBCT data for the 11 plaster blocks with teeth were acquired from the Kodak 9000 3D and ProMax 3D CBCT imaging systems. During the CBCT exposures, a 20-mm-thick water phantom was placed around the blocks to simulate soft tissue. The CBCT images were reconstructed with the proprietary software of each system. Each tooth was sectioned in the mesiodistal direction with the minimal slice thickness for each system (Table I). Mesiodistal images of all teeth were exported from the systems and saved in bitmap (BMP) format.

Viewing

Seven postgraduate students served as observers. The students twice evaluated all the images (in random order). At least 1 week separated the first and second evaluations. In a quiet room with the light dimmed, the films were assessed independently by observers on a lightbox with a ×2 magnification dental x-ray viewer. The digital and CBCT images were displayed on a 22-inch Dell E228WFP flat panel monitor (Dell, Round Rock, TX, United States) with a resolution of 1,680 × 1,050 pixels. Before observer readings, one of the investigators calibrated the monitor with the SMPTE pattern included in the DentalEye 3.0 software (DentalEye, Sundbyberg, Sweden). No extra adjustment of brightness and contrast was allowed. To display the images in a series order, the software package ACDsee v10.0 (ACD Systems International Inc., Victoria, British Columbia, Canada) was used. The display ratio of the images was 1:1. Examples of film, phosphor-plate, Promax 3D, and Kodak 9000 3D images are shown in Fig. 1. The viewing took place in a room with dimmed lights. For CBCT images that were much smaller than the monitor screen, a gray-colored barrier was used to mask the light from the background. The observers used the following 5-point rank scale to record their level of confidence regarding the presence of proximal carious lesions: 1 = definitely no caries; 2 = probably no caries; 3 = questionable; 4 = probably caries; 5 = definitely caries.

Histologic assessment

To determine the presence or absence of caries, the teeth were individually embedded in polyacrylic resin and using an Isomet low-speed saw (Buehler, Illinois, USA) with a 200-μm diamond saw blade serially sectioned (700 μm sections) in the mesiodistal direction. Two investigators assessed the tooth sections with a ×16 magnifying stereomicroscope (Zoom-630E; Changfang Optical Instrument Co., Shanghai, China). Lesions were defined by the extension of a whitish decalcified zone or a brown zone extending in the direction of the proximal pulp chamber. The following 4-point scale was used to score the status of the proximal surfaces: 0 = sound; 1 = caries in the outer half of enamel; 2 =

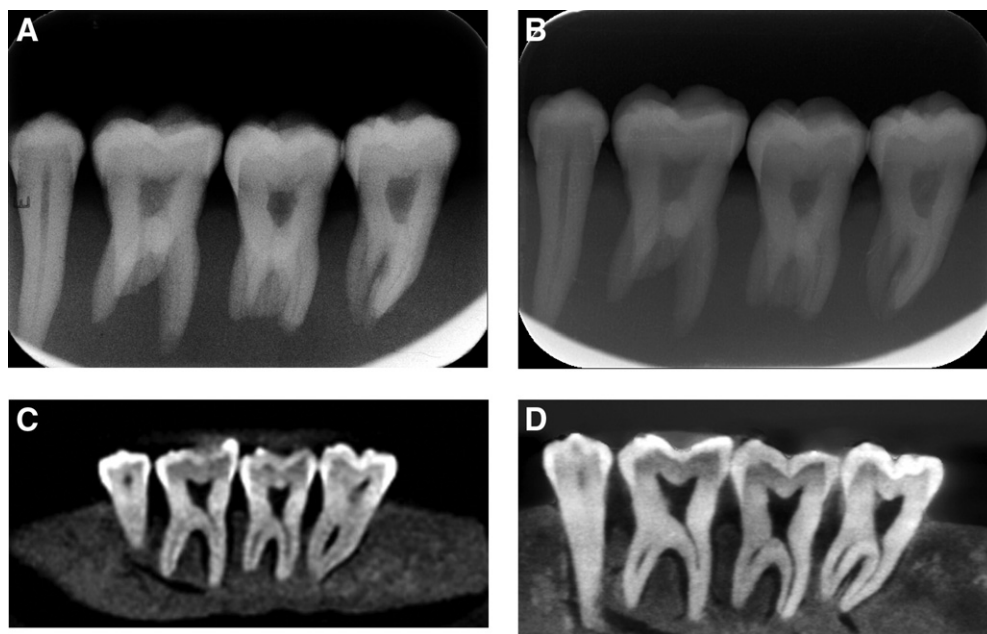


Fig. 1. Example of film (A), phosphor-plate (B), Promax 3D (C), and Kodak 9000 3D (D) images.

Table II. Area under the receiver operating characteristic curve (A_z) obtained from each observer

Observer	Film	Digital	ProMax 3D	Kodak 9000 3D
1	0.567	0.531	0.513	0.486
2	0.591	0.487	0.574	0.544
3	0.525	0.537	0.576	0.511
4	0.504	0.532	0.585	0.519
5	0.514	0.525	0.478	0.543
6	0.521	0.518	0.474	0.518
7	0.564	0.533	0.497	0.552
Mean	0.541	0.523	0.528	0.525
SD	0.033	0.017	0.049	0.023

caries in the inner half of enamel reaching but not crossing the enamel-dentin junction (EDJ); 3 = caries into dentin. The highest score from the various sections of a proximal surface was used to define the caries status of the surface. In cases where the two investigators' ratings diverged, a joint assessment was performed until consensus was reached.

Data analyses

With the histologic assessments serving as a reference standard, each observer's performance was converted into an ROC curve with SPSS v13.0 for Windows (SPSS, Chicago, IL, USA). The maximum likelihood parameters were determined and the areas under the ROC curves (A_z values) were calculated. A repeated-measures analysis of variance was used to analyze the A_z values for differences among imaging systems. Intraobserver variation was analyzed with the

Table III. P values when comparing observer performance of each modality

	Film	Digital	Kodak 9000 3D
ProMax 3D	.493	.792	.852
Film	—	.346	.386
Digital	—	—	.938

paired t test. Differences were considered to be statistically significant when $P < .05$.

Results

Histologic examination revealed that of the 78 proximal surfaces, 37 (47.4%) were sound, 24 (30.8%) had caries in the outer half of the enamel, 7 (9%) had caries in the inner half of the enamel, reaching but not crossing the EDJ, and 10 (12.8%) had dentin caries; thus, a total of 41 proximal surfaces (52.6%) were considered to be positive for caries when performing the ROC analysis.

Table II contains the individual and mean A_z values. There was no statistical difference in A_z values among the 4 imaging modalities ($P = .763$). The P values for multiple comparisons of observer performance from each modality are presented in Table III. Again, no significant difference was found among the modalities ($P \geq .346$). Figure 2 shows the ROC curves from the pooled observer performances. The ROC curve for film radiographs is slightly higher than those for the other modalities. There was neither a statistically significant

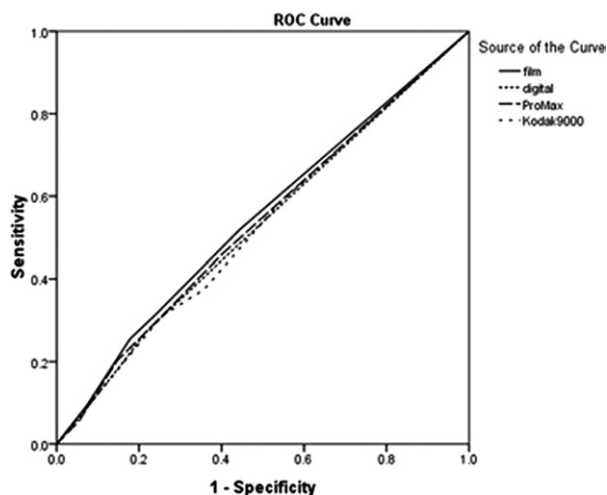


Fig. 2. Receiver operating characteristic (ROC) curves from the combined observer performances for each imaging system.

difference among (interobserver; $P = .646$) nor within (intraobserver; $P = .106$) observers.

DISCUSSION

Because CBCT is a relatively new imaging modality, its diagnostic potential for some imaging tasks is unclear. This is particularly true for the most recently released CBCT units. Clinicians may be tempted to use these new units to diagnose incipient caries—a task that is currently not recommended in SEDENTEXCT provisional guidelines. In the present *in vitro* study, incipient proximal caries detection accuracy was evaluated for 2 newly developed CBCT imaging systems. In addition, the detection accuracies of E-speed film, which is most used in China, and the Digora Optime imaging system were evaluated.

In the present study, no statistically significant difference in noncavitated proximal caries detection accuracy was found among the 4 tested imaging systems. The results are in agreement with earlier studies comparing proximal caries detection in conventional film, digital, and CBCT images^{6,11,16}; however, the film, digital, and CBCT imaging systems used in those studies were different from the ones investigated herein. In 2 of the studies,^{6,16} the detection accuracy of the proximal caries obtained from Kodak F-speed film and the Digora FMX digital imaging system were compared with those obtained from 2 CBCT imaging systems: NewTom 3G (Quantitative Radiology, Verona, Italy) and an early 3DX-Accuitomo (J. Morita Mfg. Co., Kyoto, Japan). The detectors in those CBCT systems used a configuration of scintillation screens, image intensifiers, and charge-coupled device (CCD) sensors. In those studies, the A_z values for detection of incipient

proximal caries ranged from 0.59 to 0.64. In another study,¹¹ the 3DX-Accuitomo CBCT imaging system using a complementary metal-oxide semiconductor flat panel detector was compared with a digital imaging system with a CCD detector. The results of the study indicated that neither the sensitivity ($P = .156$) nor the specificity ($P = .780$) of the 2 systems were significantly different for the detection of proximal caries limited to the enamel. In the present study, the ProMax 3D and Kodak 9000 3D CBCT imaging systems were used. Both systems use flat panel detectors composed of large pixel arrays of hydrogenated, amorphous, silicon, thin-film transistors. With these systems, x-rays are detected by a scintillator, such as terbium-activated gadolinium oxysulfide or thallium-doped cesium iodide, which converts the x-rays into visible light that is subsequently registered in a photo diode array.¹⁷ The flat panel detector can produce images with less noise and a higher spatial resolution than a detector that combines an image intensifier with a CCD.¹⁸ The Digora Optime digital imaging system, the next generation of the Digora FMX, and Kodak E-speed (rather than F-speed film) were also used in this study.

ROC analysis is often used to compare the diagnostic performance of various imaging systems.¹⁹⁻²¹ The area under the ROC curve (A_z value) is crucial and may vary from 0.5 to 1.0 (with 0.5 representing random and 1.0 representing perfect diagnostic performance). In the present study, the mean A_z values for film, digital, ProMax 3D, and Kodak 9000 3D all represented near chance performance and are typical for the assessment of incipient enamel carious lesions.²² These values may be low because the observers were postgraduate students who had only a basic knowledge of and skill in caries diagnosis, and most of the observers were more familiar with film than with digital modalities. The lack of experience by the observers may not, however, have had a major impact on our results, because it has been found that the performance of general dental practitioners and dental students is similar for the detection of proximal caries.²³

Although a comparison of the caries detection accuracies for the 2 CBCT imaging systems was not an objective of the present study, no significant difference was found between the 2 systems, which used different detectors, fields of view, voxel sizes, and slice thicknesses.

According to the principle of “as low as reasonably achievable,” radiographic examinations must be fully justified before they are performed, and evidence-based selection criteria should be considered. The present study found no advantage of CBCT over film or phosphor plates for the diagnosis of caries. Although some studies have found that the CBCT is useful for the

diagnosis of dentin caries,^{6,11} another study has indicated that the CBCT delivered a higher radiation dose (by a factor of 5-16) to the patient than a typical panoramic radiograph.²⁴ Because the dose of a single intraoral radiograph is much lower than that of a typical panoramic radiograph, the benefits obtained from a CBCT examination for proximal caries do not outweigh the radiation risks. Furthermore, the present in vitro study was performed under ideal imaging conditions that excluded object movements, metallic restorations, tissues around teeth and other parameters that can complicate the diagnosis of caries. These factors, especially metallic restorations that produce beam-hardening artifacts, may compromise image quality and diagnostic accuracy when caries diagnoses are performed for patients. A CBCT examination exclusively for proximal caries diagnosis is, therefore, not recommended.

One limitation of this study is that multiple teeth were displayed in 1 image. This violates the assumption of independence required for statistical testing. Because ours was an in vitro study with conditions carefully controlled, we think that this violation had minimal impact on our statistical testing. Other studies have also found that detection accuracy of proximal caries in digital and film radiographs is essentially similar, regardless of the alterations of tube potentials when acquiring digital and film images such as would occur if individual images of each tooth were obtained (instead of images of blocks of teeth).^{25,26} Other factors that may influence the detection accuracy of proximal caries when multiple teeth are shown in 1 image include the suggestion of a caries lesion by the black background and a psychologic effect in which the assessment of 1 proximal surface could bias the assessment of the neighboring surface; however, no such effect has been found in the literature.^{27,28}

The soft tissue-equivalent materials used in the present study were not identical. A 20-mm thick acrylic block and a water phantom were used for intraoral radiographs and CBCT images, respectively. This may have introduced a difference in scattering radiation, which could have influenced the contrast resolution of the images, although one study indicates that there is no difference in the accuracy of proximal caries detection from images made with these 2 different materials.²⁹

Several studies have demonstrated that the accuracy of dental caries detection obtained from an in vitro study can be considered to be representative of the diagnostic accuracy of dental caries in patients.^{15,29,30} We, therefore, think that the present study is representative of the diagnostic accuracy obtained in a clinical situation.

In conclusion, for the detection of noncavitated proximal caries, the accuracies of the CBCT systems

(ProMax 3D and Kodak 9000 3D), film, and phosphor plates were little better than chance performances, which are far from being clinically acceptable. When taking into account the radiation doses to which patients would be exposed, the findings of this study support the SEDENTEXCT provisional guidelines that CBCT should not be used for caries diagnoses.

The authors express their sincere appreciations to all the observers who assessed the test radiographs.

REFERENCES

- Schneiderman A, Elbaum M, Shultz T, Keem S, Greenebaum M, Driller J. Assessment of dental caries with digital imaging fiber-optic transillumination (DIFOTI): in vitro study. *Caries Res* 1997;31:103-10.
- Wenzel A. Digital radiography and caries diagnosis. *Dentomaxillofac Radiol* 1998;27:3-11.
- Nair MK, Nair UP. An in-vitro evaluation of Kodak Insight and Ektaspeed Plus film with a CMOS detector for natural proximal caries: ROC analysis. *Caries Res* 2001;35:354-9.
- Castro VM, Katz JO, Hardman PK, Glaros AG, Spencer P. In vitro comparison of conventional film and direct digital imaging in the detection of approximal caries. *Dentomaxillofac Radiol* 2007;36:138-42.
- Syriopoulos K, Sanderink GC, Velders XL, van der Stelt PF. Radiographic detection of approximal caries: a comparison of dental films and digital imaging systems. *Dentomaxillofac Radiol* 2000;29:312-18.
- Haiter-Neto F, Wenzel A, Gotfredsen E. Diagnostic accuracy of cone beam computed tomography scans compared with intraoral image modalities for detection of caries lesions. *Dentomaxillofac Radiol* 2008;37:18-22.
- Harase Y, Araki K, Okano T. Accuracy of extraoral tuned aperture computed tomography (TACT) for proximal caries detection. *Oral Surg Oral Med Oral Pathol Oral Radiol Endod* 2006;101:791-6.
- Abreu Júnior M, Tyndall DA, Platin E, Ludlow JB, Phillips C. Two- and three-dimensional imaging modalities for the detection of caries. A comparison between film, digital radiography and tuned aperture computed tomography (TACT). *Dentomaxillofac Radiol* 1999;28:152-7.
- Kalathingal SM, Mol A, Tyndall DA, Caplan DJ. In vitro assessment of cone beam local computed tomography for proximal caries detection. *Oral Surg Oral Med Oral Pathol Oral Radiol Endod* 2007;104:699-704.
- Akdeniz BG, Gröndahl HG, Magnusson B. Accuracy of proximal caries depth measurements: comparison between limited cone beam computed tomography, storage phosphor and film radiography. *Caries Res* 2006;40:202-7.
- Young SM, Lee JT, Hodges RJ, Chang TL, Elashoff DA, White SC. A comparative study of high-resolution cone beam computed tomography and charge-coupled device sensors for detecting caries. *Dentomaxillofac Radiol* 2009;38:445-51.
- Baba R, Konno Y, Ueda K, Ikeda S. Comparison of flat-panel detector and image-intensifier detector for cone-beam CT. *Comput Med Imaging Graph* 2002;26:153-8.
- De Vos W, Casselman J, Swennen GR. Cone-beam computerized tomography (CBCT) imaging of the oral and maxillofacial region: a systematic review of the literature. *Int J Oral Maxillofac Surg* 2009;38:609-25.
- SEDENTEXCT Project. Radiation protection: cone beam CT for dental and maxillofacial radiology. Provisional guidelines.

- May 2009. Available from: <http://www.sedentext.eu/content/provisional-guidelines-cbct-dental-and-maxillofacial-radiology>.
15. Li G, Qu XM, Chen Y, Zhang J, Zhang ZY, Ma XC. Diagnostic accuracy of proximal caries by digital radiographs: An in vivo and in vitro comparative study. *Oral Surg Oral Med Oral Pathol Oral Radiol Endod* 2010;109:463-7.
 16. Tsuchida R, Araki K, Okano T. Evaluation of a limited cone-beam volumetric imaging system: comparison with film radiography in detecting incipient proximal caries. *Oral Surg Oral Med Oral Pathol Oral Radiol Endod* 2007;104:412-6.
 17. Scarfe WC, Farman AG. What is cone-beam CT and how does it work? *Dent Clin North Am* 2008;52:707-30.
 18. Baba R, Ueda K, Okabe M. Using a flat-panel detector in high resolution cone beam CT for dental imaging. *Dentomaxillofac Radiol* 2004;33:285-90.
 19. Swets JA. ROC analysis applied to the evaluation of medical imaging techniques. *Invest Radiol* 1979;14:109-21.
 20. Metz CE. Some practical issues of experimental design and data analysis in radiological ROC studies. *Invest Radiol* 1989;24:234-45.
 21. Sanderink G, Huiskens R, van der Stelt P, Welander U, Stheeman S. Image quality of direct digital intraoral x-ray sensors in assessing root canal length. *Oral Surg Oral Med Oral Pathol Oral Radiol Endod* 1994;79:125-132.
 22. Wenzel A, Hintze H. The choice of gold standard for evaluating tests for caries diagnosis. *Dentomaxillofac Radiol* 1999;28:132-6.
 23. Mileman PA, van den Hout WB. Comparing the accuracy of Dutch dentists and dental students in the radiographic diagnosis of dentinal caries. *Dentomaxillofac Radiol* 2002;31:7-14.
 24. Roberts JA, Drage NA, Davies J, Thomas DW. Effective dose from cone beam CT examinations in dentistry. *Br J Radiol* 2009;82:35-40.
 25. Svenson B, Petersson A. Accuracy of radiographic caries diagnosis using different X-ray generators. *Dentomaxillofac Radiol* 1989;18:68-71.
 26. Kaeppeler G, Dietz K, Reinert S. Influence of tube potential setting and dose on the visibility of lesions in intraoral radiography. *Dentomaxillofac Radiol* 2007 36:75-9.
 27. Hintze H, Wenzel A. Clinical and laboratory radiographic caries diagnosis. A study of the same teeth. *Dentomaxillofac Radiol* 1996;25:115-8.
 28. Kamburoglu K, Senel B, Yüksel SP, Özen T. A comparison of the diagnostic accuracy of in vivo and in vitro photostimulable phosphor digital images in the detection of occlusal caries lesions. *Dentomaxillofac Radiol* 2010 39:17-22.
 29. Shi XQ, Li G. Detection accuracy of approximal caries by black-and-white and color-coded digital radiographs. *Oral Surg Oral Med Oral Pathol Oral Radiol Endod* 2009;107:433-6.
 30. Li G, Berkhout WE, Sanderink GC, Martins M, van der Stelt PF. Detection of in vitro proximal caries in storage phosphor plate radiographs scanned with different resolutions. *Dentomaxillofac Radiol* 2008;37:325-9.

Reprint requests:

Gang Li
Department of Oral and Maxillofacial Radiology
Peking University School and Hospital of Stomatology
#22 Zhongguancun Nandajie
Hai Dian District
Beijing 100081
China
kqgang@bjmu.edu.cn