


AUTHOR QUERY FORM

	Journal: YIJOM Article Number: 2002	Please e-mail or fax your responses and any corrections to: E-mail: corrections.eseo@elsevier.thomsondigital.com Fax: +353 6170 9272
---	--	---

Dear Author,

Please check your proof carefully and mark all corrections at the appropriate place in the proof (e.g., by using on-screen annotation in the PDF file) or compile them in a separate list.

For correction or revision of any artwork, please consult <http://www.elsevier.com/artworkinstructions>.

Any queries or remarks that have arisen during the processing of your manuscript are listed below and highlighted by flags in the proof. Click on the 'Q' link to go to the location in the proof.

Location in article	Query / Remark: click on the Q link to go Please insert your reply or correction at the corresponding line in the proof
Q1	Please note that figures were not sequentially cited in the text, and have been renumbered both in the text and in the artwork. Please check, and correct if necessary.
Q2	In Tables 1 and 2 please add the types to the first column. Please also check the numbers correspond to those in the text.

Thank you for your assistance.

A clinical investigation on disc displacement in sagittal fracture of the mandibular condyle and its association with TMJ ankylosis development

D. H. Duan¹, Y. Zhang²

¹Department of General Dentistry, Peking University School and Hospital of Stomatology, Beijing 100081, China;

²Department of Oral and Maxillofacial Surgery, Peking University School and Hospital of Stomatology, Beijing 100081, China

D. H. Duan, Y. Zhang: A clinical investigation on disc displacement in sagittal fracture of the mandibular condyle and its association with TMJ ankylosis development. Int. J. Oral Maxillofac. Surg. 2010; xxx: xxx–xxx. © 2010 Published by Elsevier Ltd on behalf of International Association of Oral and Maxillofacial Surgeons.

Abstract. This retrospective study evaluated the potential influence of the sagittal fracture pattern and articular disc displacement on the development of temporomandibular joint (TMJ) ankylosis. 33 sagittal fractures of mandibular condyles (SFMCs) in 19 patients were treated conservatively and were divided into non-ankylosis and ankylosis groups based on their prognosis. Using computed tomography (CT) images, the SFMCs were classified into types I, II and III, and the displacement of the articular disc was investigated using magnetic resonance imaging (MRI). There were 19 (58%) SFMCs in the non-ankylosis group: 5 were type I SFMCs, which did not show any disc displacement; the other 14 were type II SFMCs, which included 5 cases without disc displacement and 9 cases with disc displacement. In the non-ankylosis group, the lateral poles were completely or incompletely covered by the discs. There were 14 (42%) SFMCs in the ankylosis group, all of which were type III SFMCs showing disc displacement, and the lateral poles in these cases were not covered by the discs. This investigation confirmed that the disc position was highly associated with the position of the fractured fragment and that some SFMC patterns, especially type III SFMCs, indicated a high risk of TMJ ankylosis.

Key words: disc displacement; sagittal fracture; mandibular condyle; joint ankylosis..

Accepted for publication 15 November 2010

Condylar fracture accounts for 80–98% of cases of temporomandibular joint (TMJ) ankylosis^{2,12,15}. Post-traumatic TMJ ankylosis is rare with an incidence of approximately 0.4%⁷. The incidence of TMJ ankylosis is considered to be highly

related to the severity and patterns of joint injuries, and sagittal fracture of the mandibular condyle (SFMC) is noted for its susceptibility to TMJ ankylosis^{17,19}. Displacement of the articular disc results in the loss of the physical impediment to

transarticular bony fusion, thereby playing a key role in inducing TMJ ankylosis^{7,8}. Several investigations using magnetic resonance imaging (MRI) and arthroscopy have revealed the positions of the articular discs in the cases of condylar fractures^{4–}

2 Duan, and Y. Zhang

^{6,9,13,14}. The variation in the disc position according to the sagittal fracture patterns and its relation to TMJ ankylosis has not been elucidated. In this retrospective study, the authors aimed to evaluate the potential influence of the sagittal fracture pattern and joint disc displacement on the development of TMJ ankylosis.

Materials and methods

19 patients with 33 SFMCs confirmed by computed tomography (CT) were included in this study, which was conducted from January 2004 to April 2007. 13 patients underwent the complete treatment procedure at the authors' hospital, and 6 patients were treated conservatively for 2–12 months at other hospitals and were transferred to the authors' hospital with a complaint of persistent limited mouth opening.

The SFMCs were initially treated using conservative procedures, including intermaxillary elastic traction for 1–2 weeks, followed by mouth-opening exercises for at least 2 months. The patients who initially visited the authors' clinic received a duck rostra shaped, jaw dilation prop (Fig. 1) and underwent physical therapy using ultrasonic waves or infrared rays with calcium or iodide infiltration to facilitate rehabilitation. The concomitant body or symphysis fractures were treated by open reduction and plate fixation.

Although all the patients cooperated with the conservative treatment, **seven** patients showed a serious deterioration in maximal mouth opening (range, 12–25 mm); this group included **six** patients who were initially treated in local hospitals and **one** patient who underwent initial treatment at the authors' hospital. Surgical intervention was performed to release the supposed 'ankylosed' joint, and the intervention was followed by mouth-opening exercises and physical therapy. The supposed 'ankylosed' joints were validated by intraoperative visualization of fibrous adhesions or partial bony fusion between the lateral pole of the condyle and the lateral rim of the joint fossa. During the follow-up period (6–24 months; average, 8.7 months), all but **one** of the patients showed considerable improvement in mandible movement (maximal mouth opening, 30–50 mm); in the patient who did not show considerable improvement, the maximal mouth opening was 2 mm, and a second operation had to be performed to dissect the right condyle and release the left joint. The surgically repositioned disc on the right side was found to be displaced again.



Fig. 1. Duck rostra shaped, jaw dilation prop.

On the basis of the prognosis of the conservative treatment, the patients were divided into **two** groups. The non-ankylosis group contained 12 patients (6 women and 6 men) with 19 SFMCs. The ages of the patients in this group ranged from 6 years to 21 years, except for **one** patient who was 45 years old (mean age, 15 years). 11 patients had suffered injuries due to falls, and 1 patient had suffered an injury in a traffic accident. **Six** patients had concomitant body or symphysis fractures. The ankylosis group contained **seven** patients (**one** woman and **six** men) with 14 SFMCs. In this group, **three** patients had suffered injuries in traffic accidents, and the rest had suffered injuries due to

falls. The mean age of the patients in this group was 20 years (range 6–33 years), and all patients had sustained concomitant symphysis fractures.

In order to interpret the displacement of the fractured fragment on the coronal sections of the CT images, the SFMCs were classified into **three** types (Fig. 2). In type I (fissure type), the medial part of the condyle split and formed a V-shaped gap between the fragment and the lateral pole of the condyle. In type II (displacement type), the fractured fragment was anteromedially displaced, and the lateral pole of the condyle was located within the fossa. In type III (dislocation type), the fractured fragment was anteromedially displaced,

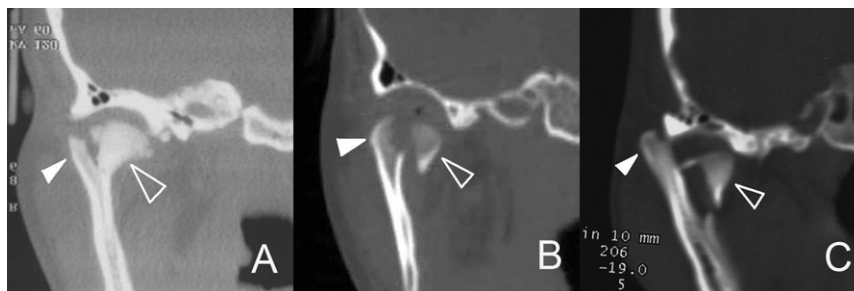


Fig. 2. CT images of SFMCs. (A) Type I, a V-shaped gap was formed between the fragment (hollow triangle) and the lateral pole (solid triangle) of the condyle. (B) Type II, the fractured fragment (hollow triangle) was anteromedially displaced, and the lateral pole was still located within the joint fossa. (C) Type III, the lateral pole (solid triangle) of the condyle was superolaterally displaced, and the fractured fragment (hollow triangle) was anteromedially displaced.

and the lateral pole of the condyle was laterally or superolaterally dislocated out of the fossa. In the MRI images, the disc position relative to the joint fossa in the sagittal section was visualized, and the SFMCs were classified into displacement and non-displacement groups. The cases were also classified into covered, incompletely covered, and uncovered groups on the basis of the relative position of the disc to both the fractured fragment and the lateral condyle pole.

Results

19 (58%) SFMCs were classified into the non-ankylosis group, of which 5 (15%)

were type I (Fig. 2A) SFMCs showing no signs of articular disc displacement (Fig. 3A and B). The remaining 14 (42%) SFMCs were type II (Fig. 2B) SFMCs, including 5 cases with no displacement of the articular disc (Fig. 3C and D) and 9 cases with disc displacement (Fig. 3E and F). In this group, all the fractured fragments (19 cases) were superiorly covered by the articular discs. The lateral poles were completely or incompletely covered by discs on the sagittal (18 cases) and coronal planes (14 cases) (Tables 1 and 2).

14 (42%) SFMCs were classified into the ankylosis group. All the fractures were type III (Fig. 2C) SFMCs showing displa-

cement of the articular discs (Fig. 4A and B). In all the cases in this group, the articular discs were anteromedially displaced and located between the fractured fragments and the cranial bases (Fig. 4A and B), while the lateral poles were in contact with the joint fossa and were not covered by the articular disc on the sagittal (12 cases) and coronal planes (6 cases) (Fig. 4C and D) (Tables 1 and 2).

Discussion

Clinically, SFMC was not commonly detected because it was easily missed on conventional radiographs^{1,16}. With the introduction of CT, the incidence of SFMC appeared to increase and was reported to be 9–29% in the cases of condylar fractures^{3,18}. Anatomically, the medial pole of the condyle extends far beyond the condylar neck and has a greater chance of being split in the sagittal plane, resulting in SFMC. The sagittal fracture line usually passes through an area between the lateral one-third and the medial one-third of the condyle³. Along with the displaced condylar fragment, the change in disc position has been investigated using arthroscopy or MRI. GOSS & BOSANQUET⁵ and JONES & VAN SICKELS⁶ indicated that even after gross displacement of the condyle, the disc appeared to be intact in the fossa. However, MERRILL⁹ and others^{4,13,14} demonstrated anteromedial disc displacement along with the fracture in the condylar fragment. In this study, the SFMCs were associated with a high rate of disc displacement (70%); there were 9 (27%) cases with type II SFMCs and 14 (42%) cases with type III SFMCs. None of the cases of type I SFMCs showed displacement of the disc, and all the cases of type III SFMCs showed displacement of the disc. Among the cases of type II SFMCs, there were five cases with no signs of disc displacement and nine cases with disc displacement. All

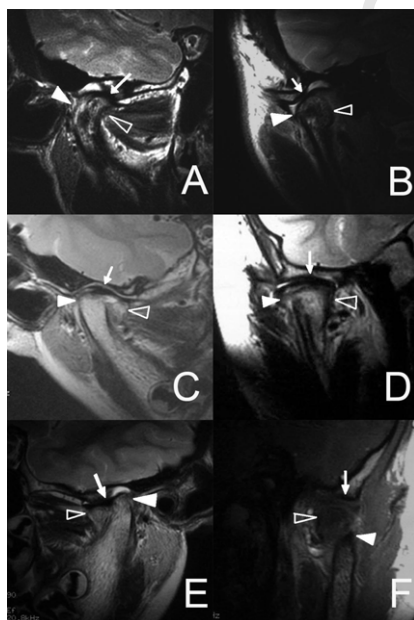


Fig. 3. MRI images of type I and type II SFMCs. (A and B) In the case of the type I SFMC, both fractured fragment (hollow triangle) and lateral pole (solid triangle) were covered by the articular disc (arrow) on the sagittal (A) and coronal (B) sections. (C and D) In the case of the type II SFMC, both fractured fragment (hollow triangle) and lateral pole (solid triangle) were covered by the articular disc (arrow) on the sagittal (C) and coronal (D) sections. (E and F) In another case of type II SFMC, the fractured fragment (hollow triangle) was covered, and the lateral pole (solid triangle) was incompletely covered by the articular disc (arrow) on the sagittal (E) and coronal (F) sections.

Q2 Table 1. The sagittal view of articular disc in available 30 joints.

	Articular disc on sagittal section		
	Covered	Incompletely covered	Uncovered
Non-ankylosis group			
Type I (5)	5	0	0
Type II (13)	5	8	0
Ankylosis group			
Type III (12)	0	0	12

Table 2. Coronal view of articular disc in available 20 joints.

	Articular disc on coronal section		
	Covered	Incompletely covered	Uncovered
Non-ankylosis group			
Type I (5)	5	0	0
Type II (9)	4	5	0
Ankylosis group			
Type III (6)	0	0	6

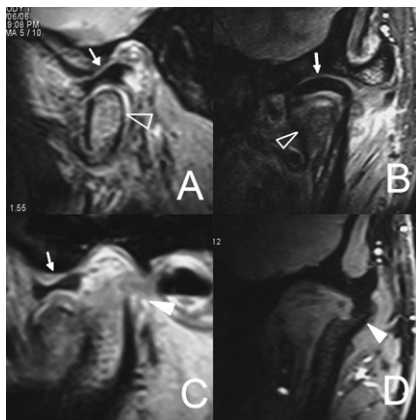


Fig. 4. MRI images of type III SFMCs. (A and B) The fractured fragment (hollow triangle) was covered by an articular disc (arrow) on the sagittal (A) and coronal (B) sections. (C and D) The lateral pole (solid triangle) was not covered by the articular disc on the sagittal (C) and coronal (D) sections.

the fractured fragments were covered superiorly by the discs, independent of the SFMC type. These findings indicated that the position of the articular disc was highly associated with the position of the fractured fragment.

Several factors were thought to contribute to post-traumatic TMJ ankylosis. Firstly, an intact disk may act as a physical impediment to transarticular bony fusion. Secondly, the type of fracture may determine the prognosis of condylar fracture. Thirdly, the age of patient at the time of injury is a key factor. Finally, the absence of mouth-opening exercise accelerates transarticular bony fusion.

This investigation revealed that SFMC was associated with a high risk of TMJ ankylosis, which was consistent with the results of previous studies^{18,19}. In this study, the SFMCs associated with TMJ

ankylosis were type III SFMCs, in which the lateral poles of the condyle are dislocated out of the joint fossa, resulting in mechanical locking and mandibular hypomobility, which subsequently accelerated TMJ ankylosis¹¹.

Apart from the influence of the fracture type, the position of the articular discs would play a more critical role. In this study, the SFMCs that progressed to ankylosis demonstrated fibrous adhesion or partial bony fusion between the lateral pole of the condyle and the lateral rim of the joint fossa rather than between the fractured fragment and the joint fossa, and these findings were validated by MR images showing that the lateral poles contacted the lateral rim of the joint fossa without the barrier of the articular disc on the sagittal (12 cases) and coronal planes (6 cases). In the cases showing good prog-

nosis without surgery, the lateral poles were completely or incompletely covered by discs on the sagittal (18 cases) and coronal (14 cases) planes. The possible reason for this phenomenon was that the absence of the articular disc between the lateral pole of the condyle and the lateral rim of the joint fossa played a key role in TMJ ankylosis, owing to the loss of a physical impediment to the transarticular bony fusion triggered by the post-traumatic response^{7,8,10}.

In conclusion, the results of this study confirmed that the displacement of the fractured fragments entailed the displacement of the articular discs in SFMCs. In addition, type III SFMCs with severe displacement of the articular disc were associated with a high risk of TMJ ankylosis and were a potential indication for surgery.

Funding

This work was funded by National Natural Science Foundation of China, No. 30572047.

Competing interests

The work this article involved in has no conflict of interest concerned.

Ethical approval

Not required for ethical approval.

References

- ANTONIADES K, KARAKASIS D, ELEPHTERIADES J. Bifid mandibular condyle resulting from a sagittal fracture of the condylar head. *Br J Oral Maxillofac Surg* 1993; **31**: 124–126.
- EL-SHEIKH MM. Temporomandibular joint ankylosis: the Egyptian experience. *Ann R Coll Surg Engl* 1999; **81**: 12–18.
- FANG Y, GU Z, CHEN W. X-ray and clinical characteristics in sagittal fracture of the mandibular condyle. *Zhonghua Kou Qiang Yi Xue Za Zhi* 2001; **36**: 250–252.
- GERHARD S, ENNEMOSER T, RUDISCH A, EMSHOFF R. Condylar injury: magnetic resonance imaging findings of temporomandibular joint soft-tissue changes. *Int J Oral Maxillofac Surg* 2007; **36**: 214–218.
- GOSS AN, BOSANQUET AG. The arthroscopic appearance of acute temporomandibular joint trauma. *J Oral Maxillofac Surg* 1990; **48**: 780–783 discussion 4.
- JONES JK, VAN SICKELS JE. A preliminary report of arthroscopic findings following acute condylar trauma. *J Oral Maxillofac Surg* 1991; **49**: 55–60.

7. LASKIN DM. Role of the meniscus in the etiology of posttraumatic temporomandibular joint ankylosis. *Int J Oral Surg* 1978; **7**: 340-345.
8. LONG X, LI X, CHENG Y, YANG X, QIN L, QIAO Y, DENG M. Preservation of disc for treatment of traumatic temporomandibular joint ankylosis. *J Oral Maxillofac Surg* 2005; **63**: 897-902.
9. MERRILL RG. Discussion: the arthroscopic appearance of acute temporomandibular joint trauma. *J Oral Maxillofac Surg* 1990; **48**: 784.
10. MIYAMOTO H, KURITA K, ISHIMARU J, GOSS AN. A sheep model for temporomandibular joint ankylosis. *J Oral Maxillofac Surg* 1999; **57**: 812-817.
11. RATTAN V. Temporomandibular joint morphology following post-traumatic ankylosis in 26 patients. *Int J Oral Maxillofac Surg* 2006; **35**: 287-288 author reply 289-290.
12. ROYCHOUDHURY A, PARKASH H, TRIKHA A. Functional restoration by gap arthroplasty in temporomandibular joint ankylosis: a report of 50 cases. *Oral Surg Oral Med Oral Pathol Oral Radiol Endod* 1999; **87**: 166-169.
13. SULLIVAN SM, BANGHART PR, ANDERSON Q. Magnetic resonance imaging assessment of acute soft tissue injuries to the temporomandibular joint. *J Oral Maxillofac Surg* 1995; **53**: 763-766 discussion 766-767.
14. TAKAKU S, YOSHIDA M, SANO T, TOYODA T. Magnetic resonance images in patients with acute traumatic injury of the temporomandibular joint: a preliminary report. *J Craniomaxillofac Surg* 1996; **24**: 173-177.
15. VALENTINI V, VETRANO S, AGRILLO A, TORRONI A, FABIANI F, IANNETTI G. Surgical treatment of TMJ ankylosis: our experience (60 cases). *J Craniomaxillofac Surg* 2002; **13**: 59-67.
16. WU XG. Sagittal fracture of the mandibular condyle (SFMC): its clinical image diagnosis. *Zhonghua Kou Qiang Yi Xue Za Zhi* 1992; **27**: 262-265 318.
17. WU XG, HONG M, SUN KH. Severe osteoarthritis after fracture of the mandibular condyle: a clinical and histologic study of seven patients. *J Oral Maxillofac Surg* 1994; **52**: 138-142.
18. YAMAOKA M, FURUSAWA K, IGUCHI K, TANAKA M, OKUDA D. The assessment of fracture of the mandibular condyle by use of computerized tomography. Incidence of sagittal split fracture. *Br J Oral Maxillofac Surg* 1994; **32**: 77-79.
19. ZHANG Y, HE DM. Clinical investigation of early post-traumatic temporomandibular joint ankylosis and the role of repositioning discs in treatment. *Int J Oral Maxillofac Surg* 2006; **35**: 1096-1101.

Address:

Yi Zhang

Department of Oral and Maxillofacial

Surgery

Peking University School and Hospital of

Stomatology

Haidian District

Beijing 100081

China

Tel: +86 13601279021

Fax: +86 162173402

E-mail: zhangyi2000@263.net

UNCORRECTED